

## TRANSMISSIBLE VENEREAL TUMOR: CELL PROLIFERATION (AGNOR) AND RESPONSE TO CHEMOTHERAPY CORRELATED WITH CYTOMORPHOLOGICAL CLASSIFICATION

### *TUMOR VENÉREO TRANSMISSÍVEL (TVT): PROLIFERAÇÃO CELULAR (AGNOR) E RESPOSTA À QUIMIOTERAPIA CORRELACIONADA À CLASSIFICAÇÃO CITOMORFOLÓGICA*

N. P. REIS FILHO<sup>1</sup>, A. A. A. TORRES<sup>2</sup>, M. P. C. SILVA<sup>3</sup>, R. F. A. VENTURA<sup>4</sup>, K. M. BASSO<sup>5</sup>, M. G. P. A. FERREIRA<sup>6</sup>, A. B. DE NARDI<sup>7</sup>, B. P. FLORIANO<sup>8</sup>, C. CALDERÓN<sup>9</sup>

#### SUMMARY

Transmissible venereal tumor (TVT) is a contagious neoplasm of round cells that occurs naturally and that affects mostly the genitalia. The TVT has been classified according to the predominant cell type as follows: lymphocytoid, plasmacytoid and mixed. Various degrees of aggressiveness with wide range of biological behavior have been described based on this cell morphology. The present study aimed to evaluate the rate of cell proliferation, by cytochemical AgNOR method, and response to chemotherapy correlated with the cytomorphological classification of TVT. The results of the 22 cases showed that TVT was identified more frequently in female, adults and mixed-breed dogs. Plasmocytoid-classified tumors required a greater number of vincristine sulfate sessions, have higher cell proliferation and were the most resistant to chemotherapy, requiring additional treatment with doxorubicin. Based on these results, we can infer that the plasmacytoid pattern might have a more aggressive behavior compared to other cell types.

**KEY-WORDS:** Chemotherapy. Oncology. Prognostic. Resistance.

#### RESUMO

O tumor venéreo transmissível (TVT) é uma neoplasia contagiosa de células redondas que ocorre naturalmente e afeta principalmente a genitália. O TVT é classificado de acordo com o tipo celular predominante da seguinte forma: linfocitóide, plasmocitóide e misto. Vários graus de agressividade com ampla gama de comportamento biológico foram descritos com base nessa morfologia celular. O presente estudo teve como objetivo avaliar a taxa de proliferação celular, pelo método AgNOR citoquímico, e a resposta à quimioterapia correlacionada com a classificação citomorfológica do TVT. Os resultados dos 22 casos mostraram que o TVT foi identificado com maior frequência em cães do sexo feminino, adultos e mestiços. Os tumores classificados como plasmocitóides necessitaram de um maior número de sessões de sulfato de vincristina, apresentaram maior proliferação celular e foram os mais resistentes à quimioterapia, necessitando de tratamento adicional com doxorubicina. Com base nesses resultados, podemos inferir que o padrão plasmocitóide pode ter um comportamento mais agressivo comparado a outros tipos de células.

**PALAVRAS-CHAVE:** Oncologia. Prognóstico. Quimioterapia. Resistência.

<sup>1</sup> NEOPET Oncologia Veterinária – Londrina/PR

<sup>2</sup> Universidade Federal de Minas Gerais - UFMG

<sup>3</sup> Universidade Estadual Paulista – UNESP/FCAV

<sup>4</sup> Universidade Estadual do Norte do Paraná – UNEP/CLM

<sup>5</sup> Universidade Filadélfia – UNIFIL/Londrina

<sup>6</sup> Universidade Estadual Paulista – UNESP/FCAV

<sup>7</sup> Universidade Estadual Paulista – UNESP/FCAV

<sup>8</sup> Centro Universitário de Ourinho – UNIFIO/Ourinhos

<sup>9</sup> Universidade Estadual do Norte do Paraná – UNEP/CLM

## INTRODUCTION

The transmissible venereal tumor (TVT) is a contagious neoplasm of natural occurrence that has been reported in dogs (DAS; DAS, 2000; NAK et al. 2005, ALBANESE, 2006; GANGULY et al. 2013). The TVT is transmitted through implantation of viable tumor cells in injured mucosal tissue and the clinical manifestation depends on the immune status of the host (ALBANESE, 2006). Thus, the external genitalia is the most commonly affected site for TVT, although extragenital reports concerning skin, oral, nasal and conjunctival mucosa have been published (DAS; DAS, 2000; NAK et al. 2005; ALBANESE, 2006; GANGULY et al. 2013).

The origin of the TVT is related to an ancestral neoplastic cell derived from a single host that was subjected to several selections and clonal expansions to form the TVT (VÁZQUEZ-MOTA et al. 2008). Since these events, a few peculiarities have been observed, such as the presence of two genetically differed groups as well as the mutation of position 963 in TP35 gene, which is found in some samples (VÁZQUEZ-MOTA et al. 2008).

In addition to those findings, a few authors have reported that TVT shows differences in cell morphology that can be associated with abnormal behavior during cytopathological analyses (AMARAL et al. 2007; BASSANI-SILVA et al. 2007; GASPAR et al. 2010; AMARAL et al. 2011). Based on these analyses and the predominant cell type, the TVT has been allocated into one of three groups known as plasmocytoid, lymphocytoid or mixed. The most aggressive form of TVT is the plasmocytoid form (AMARAL et al. 2007).

The NORs (nucleolus organizer regions) are defined as nuclear components; a group of arginophilic proteins selectively dyed by silver staining that can be easily identified as dark brown spots in the nuclear area, known as AgNORs. These regions correspond to DNA loops that contain genes responsible for the transcription of ribosome RNA and that indicate the end of mitosis, thus predicting cellular proliferation rate. The biological behavior of TVT can be estimated through AgNORs demonstration, where unfavorable prognosis is associated with increased AgNORs in the nuclear area of TVT cells (HARMELIN et al. 1995; TRERE, 2000).

The aim of this study was to analyze cellular proliferation through silver staining (AgNOR) and response to chemotherapy in regard to different cytomorphological patterns in order to characterize the biological behavior of TVT.

## MATERIAL AND METHODS

Sample and data collection was performed at the Veterinary Hospital of State University of North Paraná – Campus “Luiz Meneghel”, Bandeirantes, Paraná State, Brazil. According to Ordinance 262/2014 of the Ethics Committee (CEUA) of UENP.

Dogs diagnosed with TVT of natural occurrence through cytopathological analysis, without age, gender

or breed restriction and that had not initiated previous therapy were included in the study.

Data such as age, gender, breed, size of tumor and neutering were obtained during the first admission, as well as the owner's authorization to include the animal in the study. The subjects age was divided into four groups:  $\leq 2$ , 3 to 5, 6 to 8 and  $\geq 9$  years-old.

Tumors were further classified according to location site (genital or extragenital). The size was obtained through a three-dimension mensuration, when possible, and calculated to  $\text{cm}^3$  as follows:  $(\text{width} \times \text{length} \times \text{depth} \times \pi) / 6$  (SERŠA et al. 2003).

Samples were obtained through fine-needle aspiration (FNA). At least six samples were taken from each tumor, dried at room air and subjected to two processes: three samples were fixated with methanol and stained by Giemsa to be classified morphologically; the other three samples were stored at 95% alcohol to be further stained by silver, for AgNOR analysis.

Samples were divided based on the study by Amaral et al. (2007), to comprise three groups: plasmocytoid, lymphocytoid and mixed patterns. After Giemsa staining, 100 cells were counted by a single observer using optical microscopy at 100x. Cytomorphological patterns were considered as:

- Plasmocytoid: 60% or higher predominance of ovoid cells, broad cytoplasm, large evident nucleolus, regular chromatin and eccentric nucleus.
- Lymphocytoid: 60% or higher predominance of round cells, scarce and granular cytoplasm, presence of vacuole at cell periphery, round nucleus with rough chromatin and the presence of one or two evident nucleolus.
- Mixed: mixed cellularity between plasmocytoid and lymphocytoid patterns below 59% each.

The samples were withdrawn from the 95% alcohol and cleansed with 0,5% Triton X for further silver staining, as described by Ploton et al. (1986).

NORs count was performed in 100 cells by a single observer using the optical microscope at 100x and a “tower” method (LOPES et al. 2007), in order to prevent repeated inclusion of previously counted cells. Only dark spots distributed in the nucleus or nucleolus were counted.

Following cell count, the mean number of NORs per nucleus in each sample was again classified between plasmocytoid, lymphocytoid or mixed patterns.

The chosen treatment for all cases in this study was chemotherapy, initiated with intravenous (IV) vincristine sulfate at  $0,75 \text{ mg/m}^2$  every seven days for six weeks. Chemotherapy was delivered through a rapid bolus using an IV silicon catheter into the cephalic vein along one minute, regardless of the total volume (LORIMIER et al. 2007). Prior to all chemotherapy sessions, blood samples were withdrawn for a complete blood count. Vincristine treatment was interrupted after macroscopic regression of the tumor and absence of viable neoplastic cells on FNA analysis.

When viable cells were identified in the exam after the six session of vincristine therapy, a new chemotherapy protocol was instituted using

doxorubicin and those tumors were considered resistant types.

Doxorubicin was administered at 30 mg/m<sup>2</sup> IV every 21 days for 3 to 4 cycles. Patients weighing less than 10 kg received 1 mg/kg<sup>-1</sup> every 21 days for 3 to 4 cycles. (CALVERT et al. 1982). Drug administration was performed in a single bolus using a silicon catheter and a dark room at 0.5 mL per minute. Heart rate was constantly monitored during therapy.

Prior to doxorubicin treatment, subjects received diphenhydramine or promethazine and were constantly monitored for 20 minutes after each session.

Doxorubicin was interrupted after total macroscopic regression of the tumor and absence of viable neoplastic cells at FNA analysis, after a maximum of six sessions or after the cumulative dose of 180 mg/kg<sup>-1</sup> was reached.

Chemotherapy with either agent was interrupted when globular volume was below 25% and/or

leukocyte count was below 3000 µL<sup>-1</sup>. Both vincristine sulfate and doxorubicin were stored and prepared according to manufacturer's instructions (GUSTAFSON, et al 2013).

The statistical method was randomized and data were analyzed via analysis of variance through F test at 5% significance using the software BioEstat 5.0 (2007).

## RESULTS

The data obtained in this study are shown in Table 1. A total of 22 subjects were included in this study. Of this total, 14 (63,6%) were females and eight (36,4%) were males. The difference in frequency between genders was not significant [p>0,05]. One dog was previously neutered and the tumor was located in the genitalia.

**Table 1** - Data regarding gender, breed, age, location, size, cytomorphological classification, number of chemotherapy sessions, response to chemotherapy and AgNORs count on TVT.

Sample no.	Subject no.	Gender	Breed	Age (years)	Tumor location	Size (cm)	Cytomorphological classification	No. of VC sessions	Response to VC	No. of DX sessions	Response to DX	Total of NORs in 100 cells	NORs per nucleus (mean)
1	1	F	MONG REL	4	GENITAL IA	5	PLASMOC YTOID	6	CR	0	CR	1,058	10.58
2	2	M	SRD	4	GENITAL IA	3	LYMPHOC YTOID	3	CR	0	CR	*	*
3					NOSE	8	PLASMOC YTOID	6	PR	3	PR	574	5.74
4	3	M	MONG REL	10	GENITAL IA	3	MIXED	7	CR	0	CR	354	3.54
5	4	F	MONG REL	3.5	GENITAL IA	2	PLASMOC YTOID	3	CR	0	CR	840	8.4
6	5	F	MONG REL	6	GENITAL IA	4	LYMPHOC YTOID	4	CR	0	CR	956	9.56
7	6	M	MONG REL	4	GENITAL IA	4	PLASMOC YTOID	6	PR	2	CR	812	8.12
8	7	F	MONG REL	7	GENITAL IA	6	LYMPHOC YTOID	7	CR	0	CR	603	6.03
9	8	F	MONG REL	4	GENITAL IA	6	LYMPHOC YTOID	4	CR	0	CR	790	7.9
10	9	M	MONG REL	3	GENITAL IA	1	MIXED	2	CR	0	CR	640	6.4
11	10	F	MONG REL	3	GENITAL IA	3	PLASMOC YTOID	6	CR	0	CR	1,291	12.91
12	11	M	MONG REL	2.5	GENITAL IA	0.5	LYMPHOC YTOID	4	CR	0	CR	690	6.9
13	12	F	MONG REL	5	GENITAL IA	4	PLASMOC YTOID	6	CR	0	CR	566	5.66
14	13	F	MONG REL	6	GENITAL IA	4	MIXED	4	CR	0	CR	1,172	11.72
15	14	M	MONG REL	2	GENITAL IA	2	PLASMOC YTOID	5	CR	0	CR	1,213	12.13
16	15	M	SIBERIAN HUSKY	8	SKIN	1	PLASMOC YTOID	6	CR	0	CR	*	*
17	16	F	MONG REL	12	GENITAL IA	4	PLASMOC YTOID	6	PR	3	CR	825	8.25
18	17	F	MONG REL	3	GENITAL IA	0.5	LYMPHOC YTOID	3	CR	0	CR	*	*
19	18	F	MONG REL	5	GENITAL IA	3	PLASMOC YTOID	6	CR	0	CR	*	*
20	19	F	POODLE	4	GENITAL IA	1	LYMPHOC YTOID	6	CR	0	CR	*	*
21	20	F	YORKSHIRE TERRIER	3	GENITAL IA	1.5	PLASMOC YTOID	6	CR	0	CR	*	*
22	21	F	MONG REL	12	GENITAL IA	2	LYMPHOC YTOID	3	CR	0	CR	526	5.26
23	22	M	MONG REL	6	GENITAL IA	1	LYMPHOC YTOID	6	CR	0	CR	*	*
24					SKIN	**	PLASMOC YTOID	6	CR	0	CR	*	*

\*Inadequate samples for NOR count

\*\*Several disseminated nodules

F – Female / M – Male / VC – Vincristine / DX – Doxorubicin / CR – Complete remission / PR – Partial remission.



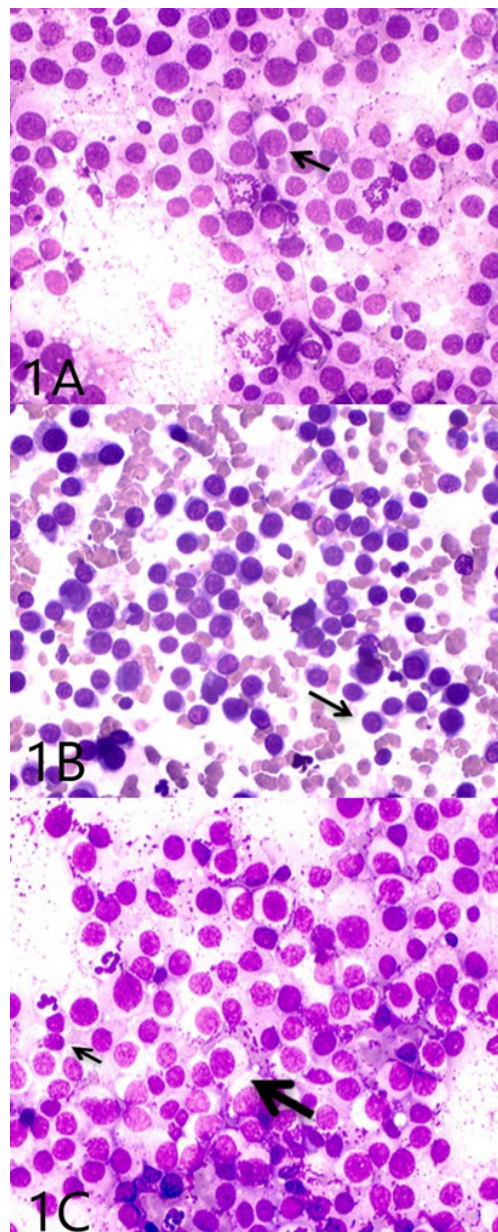
Mongrel dogs (undefined breeding) were the most frequently diagnosed with TVT ( $P < 0,05$ ), with a total of 19 subjects (86,4%) compared to other breeds (one Poodle, one Yorkshire Terrier and one Siberian Husky – 13,6%).

The age of the subjects varied between 2 and 12 years at the time of diagnosis and the most frequent was 3-5 years (54,5%,  $n = 12$ ), followed by 6-8 years (22,7%,  $n = 5$ ), over 9 years (13,6%,  $n = 3$ ) and less than 2 years (9,1%,  $n = 2$ ). The 3-5 years frequency differed significantly from the other three groups ( $P < 0,05$ ).

With regard to the clinical manifestation of TVT, 21 dogs (95,5%,  $n = 22$ ) presented tumors in the

genitalia. Of these, 19 (90,5%,  $n = 21$ ) were affected only in the genital area and two (9,5%,  $n = 2$ ) were affected also extragenitally: one in the nasal area and one in the skin. Additionally, one animal (4,5%,  $n = 22$ ) presented a primary form of TVT on the skin without any genital manifestation.

A total of 24 samples from the 22 subjects were analyzed for cytomorphological classification. Of those, 12 (50,0%) were classified as plasmocytoid (Figure 1a), nine (37,5%) as lymphocytoid (Figure 1b) and three (12,5%) as mixed (Figure 1c). The difference of frequency between the three patterns was not significant ( $P \geq 0,05$ ).



**Figure 1 - A:** Cytomorphology of transmissible venereal tumor cells: plasmocytoid pattern, ovoid morphology, broad cytoplasm and eccentric nucleus (arrow). Giemsa microscope objective lens 40x. **B:** Cytomorphology of transmissible venereal tumor cells: lymphocytoid pattern (arrow), round morphology, scarce cytoplasm, round nucleus and absence of vacuole. Giemsa microscope objective lens 40x. **C:** Cytomorphology of transmissible venereal tumor cells: mixed pattern, plasmocytoid (large arrow) and lymphocytoid (small arrow) cells. Giemsa microscope objective lens 40x.

The mean tumor volume was of 3,31 cm<sup>3</sup> with a 0,5-8,0 cm<sup>3</sup> variation. The average volume of plasmocytoid tumors was the highest, with 3.77 cm<sup>3</sup>, followed by lymphocytoid (3,00 cm<sup>3</sup>) and mixed (2,66 cm<sup>3</sup>). However, these results did not differ statistically ( $P \geq 0,05$ ).

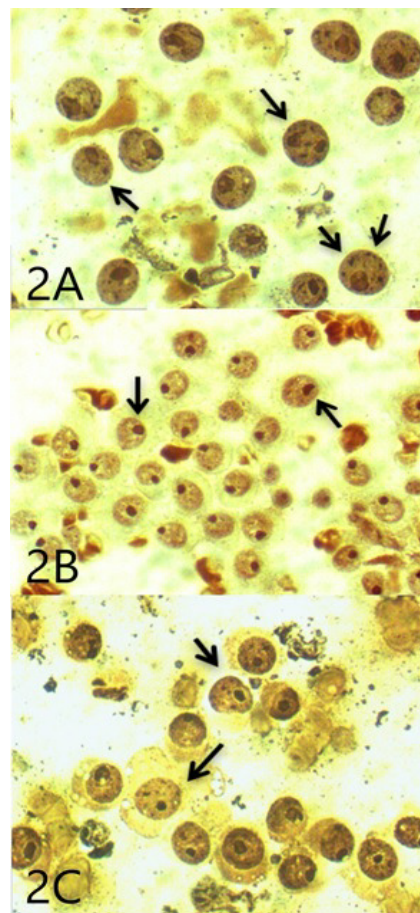
With regard to the number of chemotherapy sessions with vincristine sulfate, the mean number required for complete remission of the tumors was five sessions per animal and varied between two to seven sessions. Five to six sessions were required (5,66) for complete remission of plasmocytoid-pattern tumors, whereas four to five sessions were required for lymphocytoid and mixed patterns (4,44 and 4,33, respectively).

Of all cases subjected to chemotherapy with vincristine sulfate, only three animals required additional therapy with doxorubicin. The mean number of doxorubicin administrations was two to three sessions (2,33) in those animals. All patients with resistant tumors that required additional therapy presented the plasmocytoid-pattern morphology (n = 3). Two of the resistant-type tumors (2/3) were completely regressed after complete therapy, whereas

one required cryotherapy of the genital growth due to partial remission after chemotherapy.

Approximately 95,8% of the subjects treated achieved complete remission of the tumor and were discharged. One animal presented partial remission after complete treatment. This patient was affected by a plasmocytoid-pattern tumor of extragenital location, on the nasal area. The cytomorphological classification of the three extragenital tumors was plasmocytoid, and one of these patients did not present any genital manifestation of the neoplasm. The other two patients presented lymphocytoid-pattern morphology on the genital tumors.

The AgNOR technique was achieved in 16 samples. The mean NOR count was 8.07 NORs nucleus<sup>-1</sup> (3,54 to 12,90 NORs nucleus<sup>-1</sup>). When these results were divided between the three patterns of cell morphology, there were 9,63 NORs nucleus<sup>-1</sup> in plasmocytoid-pattern tumors (Figure 2a) (5,66 to 12,90 NORs nucleus<sup>-1</sup>), 7,48 NORs nucleus<sup>-1</sup> in mixed-pattern tumors (Figure 2c) (3,54 to 11,70 NORs nucleus<sup>-1</sup>) and 6,89 NORs nucleus<sup>-1</sup> in lymphocytoid-pattern tumors (Figure 2b) (5,26 to 9,56 NORs nucleus<sup>-1</sup>). The differences in cytomorphological classification were not significant ( $P \geq 0,05$ ).



**Figure 2 - A:** Nucleolus organizing region (NOR; arrows) indicating the cellular proliferation index in plasmocytoid (a), lymphocytoid (b) and mixed patterns (c). AgNORs microscope objective lens 100x. **B:** Nucleolus organizing region (NOR; arrows) indicating the cellular proliferation index in lymphocytoid pattern. AgNORs microscope objective lens 100x. **C:** Nucleolus organizing region (NOR; arrows) indicating the cellular proliferation index in mixed pattern. AgNORs microscope objective lens 100x.

## DISCUSSION

Although there is no evident predisposition for TVT regarding gender (DAS; DAS, 2000), a few authors have reported higher prevalence in females, since one affected male can transmit the disease to several other females. Additionally, the bitch usually accepts a considerable number of male partners during her fertile period, which causes her chances of mating with an infected male to be higher (SILVA et al., 2007; GANGULY et al., 2013). This possibility was clinically observed in our study, although there was no significance in the results to support it.

Previous reports demonstrated that there is no predisposed breed in regard to TVT, but there are risk groups that include crossbred, unneutered animals and dogs with access to streets (SILVA et al., 2007; GANGULY et al., 2013). These characteristics are corroborated by the subjects of our study, since the number of mongrel dogs diagnosed with the disease was considerably higher than other breeds.

The frequency of TVT incidence shown in dogs between 3 and 5 years of age can be ascribed to sexual maturity and increased sexual activity at that age, compared to other ranges that are expected to be less active (DAS; DAS, 2000; SILVA et al., 2007; GANGULY et al., 2013).

The genitalia is the most commonly affected location for the TVT, although extragenital manifestations were also observed in this study. Dogs maintain a habit to lick and sniff others, which is a factor to be considered and can function as a source of transmission (DAS; DAS, 2000; GANGULY et al., 2013). Extragenital tumors with no primary genital involvement are rare, but can occur, since licking, scratching and other types of contact between susceptible and affected animals are potential forms of transmission (DAS; DAS, 2000; REIS FILHO et al., 2011a; GANGULY et al., 2013).

The plasmocytoid pattern is the most frequently reported of the possible manifestations and our results are in accordance with those found by Amaral et al. (2007) and Gaspar et al. (2010). However, lymphocytoid- and mixed-pattern tumors are distinctively frequent among reports. The reports of Gaspar et al. (2010) and Amaral et al. (2011) have demonstrated a higher frequency on the incidence of mixed-pattern tumors compared to the lymphocytoid pattern. These divergences require special attention, since there are two geographically distributed lineages of TVT. This allows one to hypothesize that there might be a higher incidence of a given lineage on one location compared to another. However, more studies regarding these possibilities are still in order (REIS FILHO, 2011b).

Nak et al. (2005) have reported a mean diameter of 0,5 to 5 cm for TVTs. In our study, plasmocytoid-pattern tumors were visually larger compared to the other types, however no significant differences were found between measures. The size can be directly related to the response to therapy. Larger tumors are mostly ulcerated and contaminated, in addition to producing high amounts of immune suppressors, which

can delay remission (SCARPELLI et al., 2010). Mukaratirwa et al. (2006) have reported larger tumors in remission phase compared to those in progression phase and thus it was not possible for these authors to correlate tumor size with biological behavior, which corroborates the findings of our study.

Plasmocytoid-pattern tumors require a higher number of vincristine sulfate sessions in most of the cases, compared to other patterns. Although the mean number of vincristine sessions was lower in the lymphocytoid group, some patients required additional therapy with doxorubicin. This can be explained by individual response to treatment, which is related to a number of factors, such as immune status (NAK et al., 2005; SCARPELLI et al., 2010; VALLADÃO et al., 2010). The TVT requires an average of five sessions of vincristine sulfate to achieve full remission, however this number can vary considerably between one and 16 depending on tumor size and age of the patient (SCARPELLI et al., 2010; VALLADÃO et al., 2010).

Vincristine sulfate is an effective, safe and convenient chemotherapeutic agent for TVT treatment which provides the greatest survival rate and best response as a single agent compared to multi-chemotherapy (DAS; DAS, 2000; GANGULY et al., 2013). In this study, the response to vincristine treatment was considered satisfactory, since 95,8% of the subjects achieved complete remission of the tumor. Similar findings were reported by Nak et al. (2005) after two to seven sessions of weekly chemotherapy using vincristine sulfate at 0,025 mg kg<sup>-1</sup>, where full remission was accomplished in 84% cases. Calvert et al. (1982) and Harmelin et al. (1995) also described the use of these dosages.

The plasmocytoid-pattern TVT behaves as a frequent metastatic tumor, capable of developing in extragenital tissue and is thus considered the most aggressive type of TVT (AMARAL et al., 2007; GASPAR et al., 2010). Furthermore, this type of cellularity is reportedly resistant to propolis and vincristine sulfate (AMARAL et al., 2007; BASSANI-SILVA et al., 2007). More recently, Amaral et al. (2011) have found increased DNA lesions in lymphocytoid TVT through comet test, compared to the other two patterns. This result suggests that the plasmocytoid type has a greater proliferative activity and mitotic rate and therefore it would be a progression of the lymphocytoid type. If so, the prognosis would be more satisfactory with the latter, due to the greater incidence of apoptosis (AMARAL et al., 2011).

Gaspar et al. (2010) have observed that P-glycoprotein is highly expressed by the plasmocytoid-pattern TVT, which can be associated with greater chances of developing resistance to chemotherapy. Furthermore, increased expression of P-glycoprotein is usually reported with unsatisfactory prognosis since this protein pumps the drug molecule outwards the neoplastic cell, thus impairing its action (GASPAR et al., 2010).

The fact that all patients receiving additional therapy with doxorubicin were diagnosed with predominance of plasmocytoid-pattern tumors can be related to the factors of aggressiveness previously

described. However, the response to this rescue therapy was 67%, which might be an underestimated number, considering the few subjects studied. Nevertheless, the results of this study suggest that doxorubicin can be indicated as the treatment of choice for cases of resistance, corroborating other studies (DAS, DAS; 2000, NAK et al. 2005; GANGULY et al., 2013). Doxorubicin is an antineoplastic drug with ample applicability in veterinary oncology due to its potential to penetrate various tissues and due to its action over several phases of the cell cycle. Therefore, adequate remission is expected in resistant types of TVT (GUSTAFSON, PAGE; 2013, HUPPES et al., 2014).

Pawaiya et al. (2006) have found a mean proliferative activity of 12,01 NORs nucleus<sup>-1</sup> during silver staining analyses of naturally occurring TVTs, which discretely differs from the findings of this study (8.07 NORs nucleus<sup>-1</sup>). The difference can be explained by the type of counting, since our study used manual counting and those authors used a computerized counting technique.

The differences in NOR count was not significant when compared between cytomorphological patterns. However, an evident difference was observed between the plasmocytoid and lymphocytoid patterns. Plasmocytoid-pattern TVTs presented higher indexes of cellular proliferation. Such finding can be associated to the more aggressive behavior of this neoplasm, seeing that the higher index is usually related to the higher aggressiveness of the tumor. Metastatic and relapsed TVTs present a higher NORs count per nucleus compared to primary tumors (HARMELIN et al., 1995).

The results of this experiment corroborate the previous descriptions of AgNOR technique, which has been successfully employed to differentiate tumors with more aggressive behavior (CROCKER et al., 1989; TRERE, 2000; VAJDOVICH et al., 2004). In this study, we observed that the TVTs with higher NOR count were associated with the greater requirement of chemotherapy sessions, including those that showed resistance. However, AgNOR is currently being discarded as new prognostic markers (survivine, caspase-3, Bcl-6, Bcl-2, Ki-67 and COX-2) have shown to be important in assessing TVT patients during therapy and further after (BASSANI-SILVA et al, 2008).

## CONCLUSION

We conclude that cytomorphological classification of transmissible venereal tumors can be a direct influence on response to chemotherapy and even induction of resistance to vincristine sulfate. However, a larger study with a greater number of subjects is necessary. Plasmocytoid-pattern tumors require a greater number of chemotherapy sessions and are more capable of developing in extragenital tissues, which characterizes a more aggressive behavior. Additionally, increased NOR count is associated with plasmocytoid cells, which suggests faster proliferation. After different cytomorphological patterns and more aggressive behaviors have been found, studies with a

greater number of subjects are important in order to classify TVTs, choose chemotherapy protocols of higher precision and predict the prognosis of indolent cases.

## ACKNOWLEDGEMENTS

The authors would like to thank Araucaria Foundation for the financial support and the Animal Protection Association of Bandeirantes – Paraná State for supporting this research.

## REFERENCES

- ALBANESE, F.; SALERNI, F. L.; GIORDANO, S.; MARCONATO, L. Extragenital transmissible venereal tumour associated with circulating neoplastic cells in an immunologically compromised dog. *Veterinary and Comparative Oncology*, v. 4, p. 57–62, 2006.
- AMARAL, A. S.; BASSANI-SILVA, S.; FERREIRA, I.; FONSECA, L. S.; ANDRADE, F. H. E.; GASPAR, L. F. J.; ROCHA, N. S. Cytomorphological characterization of transmissible canine venereal tumor. *Revista Portuguesa de Ciências Veterinárias*, v. 102, p. 253-260, 2007.
- AMARAL, A. S.; FERREIRA, I.; COLODEL, M. M.; SALVADORE, D. M. F.; ROCHA, N. S. DNA damage in canine transmissible venereal tumor cells. *Revista Lusófona de Ciência e Medicina Veterinária*, v. 4, p. 1-5, 2011.
- BASSANI-SILVA, S. 2008. Imunoexpressão e citogenética do tumor venéreo transmissível natural no cão. 116f. Botucatu, SP. Tese (Doutorado em Medicina Veterinária) – Programa de Pós-graduação em Medicina Veterinária, Faculdade de Medicina Veterinária e Zootecnia, Universidade Estadual Paulista “Julio de Mesquita Filho”.
- BASSANI-SILVA, S.; SFORCIN, J. M.; AMARAL, A. S.; GASPAR L. F. J.; ROCHA, N. S. Propolis effect in vitro on canine transmissible venereal tumor cells. *Revista Portuguesa de Ciências Veterinárias*, v. 102, p. 261-265, 2007.
- CALVERT, C.A.; LEIFER, C.E.; MACEWEN, E.G. Vincristine for treatment of transmissible venereal tumours in the dog. *Journal of the American Veterinary Medical Association*. v. 181, p. 163-164, 1982.
- CROCKER, J.; BOLDY, D. A. R.; EGAN, M. J. How should we count AgNORs? Proposals for a standardized approach. *Journal of Pathology*, v. 158, p. 185-188, 1989.
- DAS, U.; DAS, A. K. Review of canine transmissible venereal sarcoma. *Veterinary Research Communications*, v. 27, p. 545-556, 2000.
- GANGULY, B.; DAS, U.; DAS, A. K. Canine transmissible venereal tumour- a review. *Veterinary and Comparative Oncology*, v. 14, n .1, p. 1-12, 2013.



- GASPAR, L. F. J.; FERREIRA, I.; COLODEL, M. M.; BRANDÃO, C. V. S.; ROCHA, N. S. Spontaneous canine transmissible venereal tumor: cell morphology and influence on P-glycoprotein expression. *Turkish Journal of Veterinary and Animal Science*, v. 34, p. 447-454, 2010.
- GUSTAFSON, D. L.; PAGE, R. L. Cancer chemotherapy. In: WITHROW, S. J.; VAIL, D. M.; PAGE, R. *Withrow and MacEwen's Small Animal Clinical Oncology*. Elsevier Health Sciences, 2013, p. 157-179.
- HARMELIN, A.; ZUCKERMAN, A.; NYSKA, A. Correlation of AgNOR protein measurements with prognosis in canine transmissible venereal tumour. *Journal of Comparative Pathology*, v. 112, p. 429-433, 1995.
- HUPPES, R.R.; PAZZINI, J.M.; DE NARDI, A.B.; CASTRO, J.; FARIA, J.; TINUCCI-COSTA, M.; AMORIM, R. Replacement of chemotherapy protocols in six dogs chemoresistant to vincristine sulfate in the treatment of transmissible venereal tumour (TVT). *European Journal of Veterinary Medicine*, v.2, p.1-8, 2014.
- LOPES, S. T. A.; BIONDO, A. W.; SANTOS, A. P. Diferencial leucocitário. In: *Manual de Patologia Clínica Veterinária*. Santa Maria, 2007, p.46-48.
- LORIMIER, L.P.; FAN, T.M. 2007. Miscellaneous Tumors. In: WITHROW, S.J.; VAIL, D.M.; PAGE, R.L. *Withrow & MacEwens Small Animal Clinical Oncology*. 4 ed. Missouri: Elsevier. p. 799-804.
- MUKARATIRWA, S.; CHIWOME, T.; CHITANGA, S.; BHEBHE, E. Canine transmissible venereal tumour: assessment of mast cell numbers as indicators of the growth phase. *Veterinary Research Communications*, v. 30, p. 613-621, 2006.
- NAK, D.; NAK, Y.; CANGUL, I. T.; TUN, B. A clinico-pathological study on the effect of vincristine on transmissible venereal tumour in dogs. *Journal of Veterinary Medicine*, v. 52, p. 366-370, 2005.
- PAWAIYA, R. V. S.; KUMAR, R.; PALIWAL, O. P.; PAWDE, A. M.; RAVINDRAN, R. Evaluation of cell proliferation markers in canine transmissible venereal tumour. *Indian Journal of Veterinary Pathology*, v. 30, p. 49-52, 2006.
- PLOTON, D.; MENAGER, M.; JEANNESSON, P.; HIMBER, G.; PIGEON, F.; ADNET, J. J. Improvement in the staining and in the visualization of the argyrophilic proteins of the nucleolar organizer region at the optical level. *Histochemical Journal*, v. 18, p. 5-14, 1986.
- REIS FILHO, N. P.; CALDERÓN, C.; TORRES, A. A. A.; GARCIA, R.L.; OLENSCKI, T. J.; BASSO, K. M. Classificação citomorfológica como fator prognóstico no tumor venéreo transmissível na região de Bandeirantes/PR. *Veterinária e Zootecnia*, v. 18, p. 30-34, 2011a.
- REIS FILHO, N. P.; CALDERÓN, C.; TORRES, A. A. A.; GARCIA, R.L.; OLENSCKI, T. J.; BASSO, K. M. Tumor venéreo transmissível cutâneo primário: relato de caso. *Veterinária e Zootecnia*, v. 18, p. 162-167, 2011b.
- SCARPELLI, K. C.; VALLADÃO, M. L.; METZE, K. Predictive factors for the regression of canine transmissible venereal tumor during vincristine therapy. *The Veterinary Journal*, v. 183, p. 362-363, 2010.
- SERŠA, G.; ČEMAŽAR, M.; MIKLAVČIČ, D. Tumor blood flow modifying effects of electrochemotherapy: a potential vascular targeted mechanism. *Radiology and Oncology*, v. 37, n. 1, 2003.
- SILVA, M. C. V.; BARBOSA, R. R.; SANTOS, R. C.; CHAGAS, R. S. N.; COSTA, W. P. Avaliação epidemiológica, diagnóstica e terapêutica do tumor venéreo transmissível (TVT) na população canina atendida no hospital veterinário da UFERSA. *Acta Veterinária Brasília*, v. 1, p. 28-32, 2007.
- TREERE, D. AgNOR staining and quantification. *Micron*, v. 31, p. 127-131, 2000.
- VAJDOVICH, P.; PSÁDER, R.; TÓTH, Z. A.; PERGE, E. Use of the argyrophilic nucleolar region method for cytologic and histologic examination of the lymph nodes in dogs. *Veterinary Pathology*, v. 41, p. 338-345, 2004.
- VALLADÃO, M. L.; SCARPELLI, K. C.; METZE, K. Clinical utility of a life quality score in dogs with canine transmissible venereal tumor treated by vincristine chemotherapy. *Arquivo Brasileiro de Medicina Veterinária e Zootecnia*, v. 62, p. 1086-1093, 2010.
- VÁZQUEZ-MOTA, N.; SIMÓN-MARTÍNEZ, J.; CÓRDOVA-ALARCON, E.; LAGUNES, L.; FAJARDO, R. The T963C mutation of TP53 gene does not participate in the clonal origin of canine TVT. *Veterinary Research Communication*, v. 32, p. 187-191, 2008.