

***SPIROCERCA LUPI* (SPIRURIDA: SPIROCERCIDAE) INFECTION ASSOCIATED
TO SECONDARY MEGAESOPHAGUS AND OBSTRUCTIVE PROCESS IN A
SENILE DOG**

**INFECCÃO POR *SPIROCERCA LUPI* (SPIRURIDA: SPIROCERCIDAE)
ASSOCIADA A MEGAESÔFAGO SECUNDÁRIO E PROCESSO OBSTRUTIVO EM
UM CÃO SENIL**

ABSTRACT

Spirocercera lupi is a nematode parasite that can be found in the esophagus and aorta of carnivores, including humans. Affected animals may develop mild to severe lesions, depending on the degree of infection, route of larval migration and the inflammatory response. The present work describes the occurrence of *S. lupi* in a 16-year old male Chow Chow dog, presenting a chronic esophagus infection, associated with a critical obstruction. After the identification of the parasite egg by faecal exam, the patient was treated with milbemycin in combination with praziquantel P.O., in days zero, seven and 28 after the diagnose. An esophagogram was also performed, confirming the secondary megaesophagus. The team of clinicians decide to perform a euthanasia due to the complication of the patient's condition, even after the anthelmintic treatment. This report is important as it describes a case after 18 years of epidemiological silence in the Metropolitan region of Curitiba, PR, Brazil. The present data aims to raise awareness about the prevalence of this zoonotic disease and the importance of a specific clinical and radiographic diagnose in dogs. It is noteworthy to report the difficulty to reduce the size of the associated esophagus mass even after a potent anthelmintic treatment.

Key words: Endoparasite. Nematode. Obstruction. Regurgitation. Spirocercosis.

RESUMO

Spirocerca lupi é um parasito nematoide que pode ser encontrado no esôfago e na aorta de carnívoros, incluindo humanos. Os animais afetados pela doença podem desenvolver de lesões leves a graves, dependendo do grau de infecção, migração larval e resposta inflamatória. O presente trabalho descreve a ocorrência do parasito em um cão Chow Chow de 16 anos de idade, com infecção crônica, apresentando megaesôfago secundário associado a uma crítica obstrução do órgão. Após a identificação do ovo do parasito, foi realizado tratamento antiparasitário oral com a combinação de milbemicina e praziquantel, nos dias zero, sete e 28 após o diagnóstico. Também foi realizado esofagograma, confirmando o megaesôfago secundário. A equipe médica decidiu pela eutanásia do cão devido a sua complicação da condição clínica quando o paciente retornou, mesmo após o tratamento com anti-helmíntico. Este relato é importante porque descreve um caso após 18 anos de silêncio epidemiológico na região metropolitana de Curitiba, Paraná, Brasil. Os presentes dados visam conscientizar sobre a prevalência dessa doença zoonótica e a importância de um diagnóstico clínico e radiográfico específico em cães. É digno de nota relatar a dificuldade em reduzir o tamanho da massa esofágica associada, mesmo após um tratamento anti-helmíntico potente.

Palavras-chave: Endoparasito. Espirocercose. Nematódeo. Obstrução. Regurgitação.

INTRODUCTION

Spirocercosis is a disease caused by *Spirocerca lupi*, a carnivorous spirurid nematode (VAN DER MERWE et al., 2008). Carnivores are infected by ingesting coprophage beetles or any infected vertebrate animals, including poultry, wild birds, lizards, rodents, hedgehogs and rabbits, which act as intermediate or paratenic hosts. The parasite is common in dogs, although, there are reports of the infection in wild carnivores, cats and other domestic animals (rarely in

humans), which are also considered definitive hosts. This infection is mostly prevalent in warm climate regions, being reported in Brazil (OLIVIERA-SEQUEIRA et al., 2002; QUESSADA et al., 2007), Israel (MAZAKI-TOVI et al., 2002), South Africa (LOBETTI, 2000) and many other countries. In Brazil, the reported prevalence of spirocercosis is just above 1% (OLIVEIRA-SEQUEIRA et al., 2002).

The lesions caused by *S. lupi* are dependent of the migration of the larvae and the persistence of the adult parasites in the infected tissues. Adults can be found in nodules or granulomas in the wall of the esophagus, aorta, stomach and other organs. Aortic lesions are considered pathognomonic, even though its typical target is the esophageal wall (CHAI et al., 2018). In severe cases, lesions of caudal thoracic vertebrae spondylitis and neoplastic transformation into fibrosarcoma, osteosarcoma and undifferentiated sarcoma have been observed (RANEN et al., 2004). This report describes the clinical finding of a severe case of spirocercosis in a domestic dog and the lack of control using a broad-spectrum anthelmintic combination.

MATERIAL AND METHODS

A 16 years old, castrated male Chow Chow dog, weighing 13.8 kg and always fed with commercial dog food, was received at the Veterinary Hospital of the Federal University of Paraná, UFPR in April 2019. The dog's guardian reported that the animal had recurrent regurgitation episodes, which started three months before. The guardian also noticed a significant weight loss in the last two months. In the physical and clinical examination, the parameters were according to the physiological analysis. The animal received parasite control medication six months prior to the first evident signs. According to the report, the dog had contact with three other dogs, which did not have the mentioned clinical signs. The guardian

reported that the animals had no access to the street, unless under supervision, and had no contact with rodents or pigeons.

The patient was submitted to radiography and coproparasitological exams. A fecal sample was collected fresh from the hospital cage and sent to the Laboratory of Veterinary Clinical Parasitology to be analyzed using the Willis-Mollay (1921) and Faust et al. (1939) techniques. A biopsy of the mass could not be performed at the Veterinary Hospital and the patient's guardian chose not to perform it elsewhere.

RESULTS AND DISCUSSION

The radiographic examination of the thorax in the laterolateral and ventrodorsal positions revealed a rounded radiopaque soft tissue mass with a regular contour of approximately 5.8 x 6.0 cm in the caudal mediastinal region (topographic portion) of the postcardial esophageal pathway (Figure 1). The mass was in the diaphragmatic-thoracic/abdominal transition, which could be also affecting the cardiac portion of the organs. Anteriorly to the mass, it was noticed a moderate gas esophageal dilatation compatible with megaesophagus (Figure 1).

Due to these findings, an esophagogram was performed by administering 15 ml of barium sulphate medium orally with a subsequent radiographic exposure. The esophagogram confirmed the presence of an esophageal mass (Figure 2), which was causing a significant luminal narrowing. A narrow line of luminal contrast medium of rectilinear appearance and slightly irregular surface of approximately 5.0 cm in length can be seen in Figure 2. Anterior to the thinning luminal area, it is possible to visualize an abrupt interruption of the contrast column, coupled with retention and dilation of the medium (Figure 2). As mentioned above, the mass reached the esophageal region and probably the cardia, as it was also visualized in the

cranial abdominal portion. It was not possible to safely define the degree of mural and/or extramural involvement of the mass.

The results from the Faust coprological exam was positive for *Spirocerca* sp. eggs, compatible to *S. lupi*., *Trichuris* sp. and *Ancylostoma* spp., were also found in high numbers. The Willis-Mollay technique did not find *Spirocerca* sp. eggs. After this, an antiparasitic treatment protocol was performed using a combination of milbemycin oxime (12.5 mg) and praziquantel (125 mg) orally, on the day of diagnosis. The medication was repeated seven and 28 days after the first dose.

A new imaging examination was performed about two months after the first radiograph. Chest X-ray at the laterolateral and ventrodorsal positions revealed a radiopaque soft tissue mass in the diaphragm of approximately 5.88 x 5.45 cm in length, confirmed by the esophagogram. There was no radiographic improvement, comparing the images of the first exam to the second one. The masses in the esophageal region were still very similar. Therefore, and due to the complication of the patient's condition, the clinical team suggested to perform the euthanasia. Unfortunately, the guardian did not authorize the necropsy of the animal.

Although canine spirocercosis is found worldwide (VAN DER MERWE et al., 2008), there are no recent reports of its occurrence in Brazil. In the state of Paraná, the last report was published by Molento et al. (2001). Most recently, Fonseca et al. (2012) reported in the state of São Paulo. An uncomplicated oral infection can be subclinical or show unspecific symptoms, such as regurgitation and weight loss. Therefore, a more specific exam has to be performed to determine the cause of dysphagia and the association with the development of an esophageal mass (MAZAKI-TOVI et al., 2002). These findings were consistent with the clinical signs reported by the dog's guardian, who mentioned persistent regurgitation in the last three months, including significant weight loss.

The finding of a chest mass located in the caudal mediastinal region, obtained in this study by simple radiography and confirmed by the esophagogram, corroborates with other studies (SASANI et al., 2012). Anteriorly to the mass, there was esophageal dilatation compatible to megaesophagus, but with no other changes. According to Sasani et al. (2012), typical clinical and radiological findings of spirocercosis are a caudal esophageal mass, aortic artery lesions, and thoracic spondylitis. Additional reported complications of spirocercosis can include secondary megaesophagus.

In this report, we found a narrow line of luminal contrast medium with a rectilinear aspect and a slightly irregular surface that reached the gastric cavity. These findings corroborate to other authors, as Gosling and Gracia (1983), using contrast radiography, demonstrated a sinuous retention of the contrast medium at the last third part of the thoracic esophagus. Fonseca et al. (2012), described a partial contrast medium retention that occurred in the portion just before the mass, located in the last third part of the esophagus, due to parasite infection.

Spirocerca lupi eggs are difficult to detect in direct or flotation methods using sugar and salt solutions, therefore it requires specific laboratory techniques. As reported by Cabrera and Bailey (1964), the modified Stoll technique makes egg visualization easier because it makes the solution clearer. The flotation method with sodium nitrate solution with a density of 1.36g/mL or 33% supersaturated zinc sulfate has the characteristic of concentrating the parasite eggs (VAN DER MERWE et al., 2008). Fonseca et al. (2012) reported that the Willis-Mollay method is less efficient, as also reported by Cabrera and Bailey (1964), when comparing this technique to the Hoffman method. In the present study, only the Faust techniques was positive for *S. lupi* eggs, in agreement to the other authors regarding the low specificity of the Willis-Mollay test.

Over the years, several different medications have been used to treat spirocercosis. In the last decade, the efficacy of doramectin has been reported (LOBETTI, 2012). However, the

drug is prohibited in Collies and related breeds due to its high toxic penetration to the blood-brain barrier. A member of the same family, orally administered milbemycin oxime is safer, relatively inexpensive and effective against *S. lupi* (KELLY et al., 2008). Okanishi et al. (2013), have demonstrated the efficacy of milbemycin oxime (0.5 mg/kg) in the treatment of spirocercosis. However, in the present report, it was not possible to accurately evaluate the efficacy of the treatments, due to the deprived clinical condition of the animal and the lack of the necropsy data. Fonseca and Laisse (2014) also reported that a patient did not react positively to the treatment, and had to be euthanized due to the worsening of its clinical status. Therefore, we suspect that *S. lupi* is not being eliminated after treatment from the animals, as the associated lesions are also not reduced in size. We understand the difficulty to run clinical trials, but we need more studies to better determine the chemical effect on parasite numbers, which may be directly associated with a decrease of the inflammation of the esophagus.

CONCLUSIONS

The present work reports the first clinical case of spirocercosis in the region of Curitiba, an area of 3 million people. To date, the region presented zero risk for this zoonotic parasite. However, this work serves as a warning for veterinarians about the prevalence of this zoonotic disease and the importance of a specific clinical and radiographic diagnose in dogs (i.e. regurgitation, presence of esophageal mass). These symptoms should be used as indicators of *S. lupi* parasitism in dogs with a persistent chronic infection. It was critical to determine the difficulty to reduce the size of the associated esophagus mass even after a potent anthelmintic treatment.

REFERENCES

- BAILEY, W.S. Parasites and cancer: sarcoma in dogs associated with *Spirocerca lupi*. **Annals of the New York Academy of Science**, v. 108, p. 890–923, 1963.
- BAILEY, W.S. *Spirocerca lupi*: a continuing inquiry. **The Journal of Parasitology**, v. 58, p. 3–22, 1972.
- CABRERA, D.J; BAILEY, W.S. A modified Stoll technique for detecting eggs of *Spirocerca lupi*. **Journal of the American Veterinary Medical Association**, v.145, p. 573–575, 1964.
- CHAI, O.; YAS, E.; BRENNER, O. et al. Clinical characteristics of *Spirocerca lupi* migration in the spinal cord. **Veterinary Parasitology**, v. 253, p.16-21, 2018.
- FONSECA, E.J.; AMARANTE, E.V.G.; ABOUD, L.C.S. et al. Fatal esophageal fibrosarcoma associated to parasitism by spirurid nematode *Spirocerca lupi* in a dog: a case report. **Journal of Parasitic Diseases**, v.36, n.2, p.273–276, 2012.
- FONSECA, D.C.; LAISSE, C.J.M. Spirocercosis in a stray dog in Matola city, Southern Mozambique. **Revista de Patologia Tropical**, vol. 43, n. 4, p.492-499, 2014.
- GOSLING, E.T.; GRACIA, A. Diagnostico precoz y tratamiento de la spirocercosis (*Spirocerca lupi*). **Veterinária Tropical**, v.8, p.57–69, 1983.
- KELLY, P.J.; FISHER, M.; LUCAS, H. et al. Treatment of oesophageal spirocercosis with milbemycin oxime. **Veterinary Parasitology**, v.156, p.358–360, 2008.
- LOBETTI, R.G. Survey of the incidence, diagnosis, clinical manifestations and treatment of *Spirocerca lupi* in South Africa. **Journal of the South African Veterinary Association**, v.71, p.43–46, 2000.
- LOBETTI, R.G. Successful resolution of oesophageal spirocercosis in 20 dogs following daily treatment with oral doramectin. **The Veterinary Journal**, v.193, p.277-278, 2012.

QUESSADA, A.M.; SILVA, F.L.; SOUZA, A.B. et al. Surgical removal of the granuloma of *Spirocerca lupi*. **Acta Scientiae Veterinariae**, v.35, n.3, p.385-387, 2007.

MAZAKI-TOVI, M.; BANETH, G.; AROCH, I. et al. Canine spirocercosis: clinical, diagnostic, pathologic and epidemiologic characteristics. **Veterinary Parasitology**, v.107, p.235–250, 2002.

MOLENTO, M.B.; WERNER, P.R.; CARVALHO FILHO, A.P. Achado de *Spirocerca lupi* em canino: relato de caso. In: VI Jornada de Medicina Veterinária da Unipar, 2001, Umuarama. **Arquivos de Ciências Veterinárias e Zoologia da UNIPAR** (Impresso), v. 4. p. 247, 2001.

OLIVEIRA-SEQUEIRA, T.G.C.; AMARANTE, A.F.T.; FERRARI, T.B. et al. Prevalence of intestinal parasites in dogs from São Paulo State, Brazil. **Veterinary Parasitology**, v.103, p.19–27, 2002.

OKANISHI, H.; MATSUMOTO, J.; AOKI, H. et al. Successful resolution of esophageal granulomas in a dog infected with *Spirocerca lupi*. **The Journal of Veterinary Medical Science**, v. 75, p. 1629-1632, 2013.

RANEN, E.; LAVY, E.; AIZENBERG, I. et al. Spirocercosis associated esophageal sarcomas in dogs. A retrospective study of 17 cases (1997–2003). **Veterinary Parasitology**, v.119, p.209–221, 2004.

RIDGWAY, R.L.; SUTER, P.F. Clinical and radiographic signs in primary and metastatic oesophageal neoplasms of the dog. **Journal of the American Veterinary Medical Association**, v. 174, p. 700–704, 1979.

SASANI, F.; JAVANBAKHT, J.; JAVAHERI, A. et al. The evaluation of retrospective pathological lesions on spirocercosis (*Spirocerca lupi*) in dogs. **Journal of Parasitic Diseases**, v. 38, n.2, p.170-173, 2012.

SEIBOLD, H.R.; BAILEY, W.S.; HOERLEIN, B.F. et al. Observations of the possible relation of malignant esophageal tumors and *Spirocerca lupi* lesions in the dog. **American Journal of Veterinary Research**, v.16, p. 5–14, 1955.

STEPHENS, L.C.; GLEISER, C.A.; JARDINE, J.H. Primary pulmonary fibrosarcoma associated with *Spirocerca lupi* infection in a dog with hypertrophic pulmonary osteopathy. **Journal of the American Veterinary Medical Association**, v.182, p. 496–498, 1983.

VAN DER MERWE, L.L.; KIRBERGER, R.M.; CLIFT, S. et al. *Spirocerca lupi* infection in the dog: A review. **The Veterinary Journal**, v.176, p. 294-309, 2008.

WANDERA, J.G. Further observations on canine spirocercosis in Kenya. **The Veterinary Record**, v. 99, p.348–351, 1976.

FIGURES

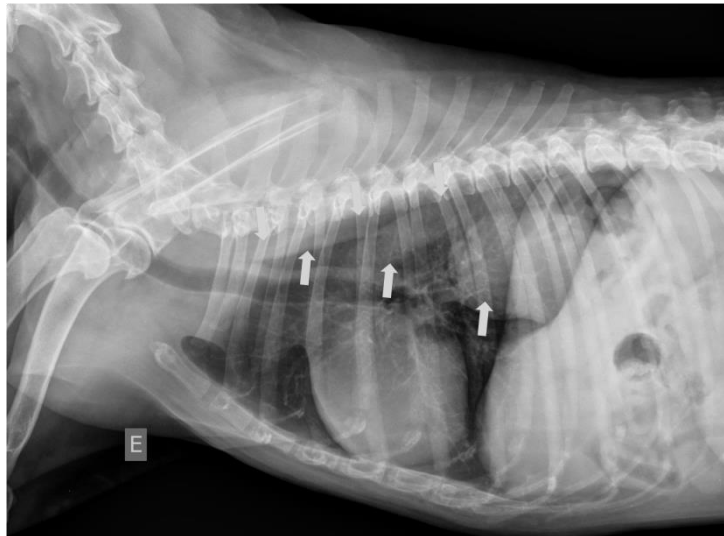


Figure 1 - Chest X-ray from the left laterolateral projection. Mass with radiopacity of soft tissue, rounded, regular contour in the caudal mediastinal region, topographic portion of the postcardial esophageal pathway (Arrow). Anteriorly the mass, moderate gas esophageal dilatation, compatible with megaesophagus (Arrow).

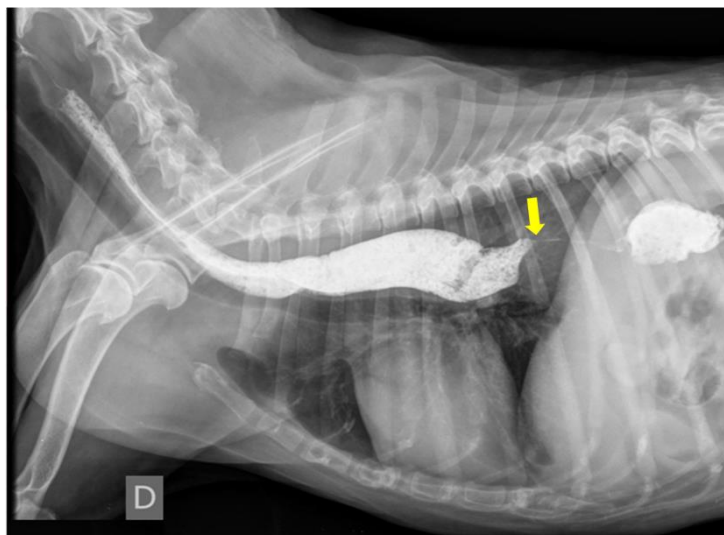


Figure 2 - Contrast-enhanced chest X-ray (esophagogram). Narrowing of the luminal contrast medium line, rectilinear in appearance and slightly uneven surface (Arrow). Anterior to the thinning area (luminal) by contrast means, abrupt interruption of the contrast column ally to retention and dilation of the esophagus (Arrow).