

1 **CLINICAL SAFETY OF DOXYCYCLINE TREATMENT IN NILE TILAPIA**
2 **(*Oreochromis niloticus*)**

3
4 (SEGURANÇA CLÍNICA DO TRATAMENTO COM DOXICICLINA EM TILÁPIA DO NILO
5 (*Oreochromis niloticus*)
6
7

8 **Summary** - This study aimed to evaluate the clinical safety of treatment with different doses
9 of Doxycycline (Sandoz Farmececutive Industry from Brazil Ltd.), administered orally
10 incorporated into the diet of Nile tilapia, *Oreochromis niloticus*. For this purpose, 75 Nile
11 tilapia (*Oreochromis niloticus*) were used, approximately 300 grams, from the Aquabel
12 company, located in Porto Ferreira/SP, from the same spawning area, conditioned in 15 tanks
13 (n=5), with a capacity of 100 liters (L) of water each, supplied with chlorine free running
14 water, with the following treatments: T0 (Control - not treated with Doxycycline); T1, T2, T3
15 and T4 (treated with 10, 20, 40 and 80mg/kg of Doxycycline (bodyweight), respectively), in
16 which 5 animals were sampled per treatment in 3 periods: 2, 4 and 8 days post-treatment
17 (DPT). Blood samples were collected for hemogram determination and serum biochemical
18 evaluation, as well as spleen, liver and kidneys (cranial and caudal) for somatic and
19 histopathological evaluation. The results showed transient clinical changes in fish treated for
20 eight consecutive days with a dose of 80mg/kg of bodyweight, which showed an increase in
21 aspartate aminotransferase (AST) enzymatic activity and a decrease in circulating hemoglobin
22 values, however the doses tested in tilapia showed a good clinical safety margin.
23

24 **Keyword:** Antimicrobial. Serum biochemical. Hemogram. *Oreochromis niloticus*. Clinical
25 safety.
26

27 **Resumo** - Este estudo teve por objetivo avaliar a segurança clínica do tratamento com
28 diferentes doses de Doxiciclina (Sandoz do Brasil Indústria Farmacêutica Ltda.), administrada
29 via oral incorporada à ração em tilápias do Nilo, *Oreochromis niloticus*. Para tal, foram
30 utilizadas 75 tilápias no Nilo (*Oreochromis niloticus*), ±300g, oriundas da empresa Aquabel,
31 localizada em Porto Ferreira/SP, da mesma desova, acondicionadas em 15 tanques (n=5), com
32 capacidade de 100 L de água cada, abastecidos com água corrente desprovida de cloro, sendo
33 constituído os seguintes tratamentos: T0 (Controle - não tratado com Doxiciclina); T1, T2, T3
34 e T4 (tratados com 10, 20, 40 e 80mg/kg de p.v. de Doxiciclina, respectivamente), em que 5
35 animais foram amostrados por tratamento em 3 períodos: 2, 4 e 8 dias pós-tratamento (DPT).
36 Foram coletadas amostras de sangue para determinação do hemograma e avaliação do

37 bioquímico sérico, além de órgãos como baço, fígado e rins (cranial e caudal) para avaliação
38 somática e histopatológica. Os resultados mostraram alterações clínicas transitórias em peixes
39 tratados durante oito dias consecutivos com a dose de 80mg/Kg de p.v., os quais apresentaram
40 aumento de atividade enzimática de aspartato aminotransferase (AST) e diminuição dos
41 valores circulantes de hemoglobina, entretanto as doses testadas nas tilápias apresentaram boa
42 margem de segurança clínica.

43

44 **Palavras chave:** Antimicrobiano. Bioquímico sérico. Hemograma. *Oreochromis niloticus*.
45 Segurança clínica.

46

47

48

49

50

51

52

53

54

55

56

57

58

59

60

61

62

63

64

65

66

67

68

69

70 1. INTRODUCTION

71

72 The development of synthetic antimicrobials of the tetracycline class, initiated with
73 doxycycline in 1967, which is a systemic antibiotic that benefits over other members of the
74 Tetracycline family as well as better oral absorption and prolonged serum half-life (18-22
75 hours) (Holmes et al., 2009). Besides, compared to the original tetracycline, the synthetics
76 have better dosage plan and are more easily absorbed when ingested with food (Smith and
77 Leyden, 2005).

78 Doxycycline has activity against a wide range of Gram-positive, Gram-negative and
79 'atypical' bacteria, as well as some protozoa such as malaria (Holmes et al., 2005). It is a drug
80 well tolerable and used largely in the treatment of infectious diseases as acne, sexually
81 transmitted diseases, respiratory tract infections and several important potential biological
82 warfare agents (Smith and Leyden, 2005; Holmes et al., 2009).

83 Doxycycline is considered a bacteriostatic drug, because its action mechanism occurs the
84 inhibition of the synthesis of bacterial proteins, reversibly binding to the 30S ribosomal
85 subunit and preventing the association of aminoacyl-tRNA with the bacterial ribosome
86 (Holmes et al., 2009). The recommended dose for humans is initially 200 mg daily, followed
87 by a maintenance dose of 100 mg daily (or twice a day for serious infections, but the
88 maximum dose recommended is 300 mg per day. It can be administered orally or
89 intravenously (Holmes et al., 2009). Its main adverse effects are gastrointestinal disturbances,
90 esophagitis and photosensitivity, however, those can be avoided with careful attention to
91 correct administration (Smith and Leyden, 2005).

92 In pisciculture production systems, when there are outbreaks of infectious diseases, one of
93 the alternatives of treatment is the use of antimicrobials (Oliveira et al., 2021). The safety and
94 tolerance of drugs has always been an interest and concern to who receive it, but mainly
95 prescribes the drugs, because the exact incidence of specific side effects is hard to evaluate, so

96 it is necessary several studies and clinical tests on animals to confirm (Owens and Ambrose,
97 2005). However, medicines registered for use in pisciculture are scarce (Oliveira et al., 2021).
98 According to the Food and Drug Administration (FDA), regulatory body of the use of drugs
99 in United States, the only antimicrobials approved for use in aquaculture are oxytetracycline,
100 florfenicol and sulfadimethoxine associated with ormethoprim (FDA, 2022). In this
101 perspective, harmlessness is an extremely important factor in pharmacological studies
102 (Aracati et al., 2021) and the use in discrimination antimicrobials, as high-dose, are limited by
103 very high risk of toxicity, resistance selection and low efficiency (Bassetti et al., 2018).
104 Therefore, it is extremely important to study safety of the aquatic environment and clinical
105 safety of antimicrobials in fish, that generally are performed through hematological exams,
106 histopathological and biochemical tests in which are techniques that evaluate the essential
107 parameters of the biological conditions of fish.

108

109 **2. MATERIAL AND METHODS**

110 **2.1. Fish and packaging**

111

112 For the clinical study of Doxycycline safety, were used 75 Nile tilapia (approximately
113 300g) from the same spawning from the Aquabel farm (Porto Ferreira, SP, Brazil),
114 conditioned in 15 tanks (100 liters of water each, n=5) filled with chlorine free running water
115 from an artesian well with a recirculation system with a flow rate of 1 liter per minute. After
116 being transported to the appropriate tanks, the fish were acclimatized for 15 days, the time
117 necessary for the plasma cortisol concentration and osmolarity return to baseline levels. In the
118 first three days of acclimatization, the animals were bathed with a NaCl solution at a
119 concentration of 6.0 g/L (Carneiro and Urbinati, 2001). The animals received pelleted
120 commercial feed with 36% crude protein (Nutripiscis® - Presence Company), constituting the
121 basal diet. The fish were fed twice a day, at 8:00 am and 5:00 pm, corresponding to 2% of the

122 biomass in the tanks. Water quality parameters were determined twice a day throughout the
123 experimental period using pHmeter YSI-63 and oximeter Y-55, and their values remained
124 within the range suitable for the well-being of tropical fish (Boyd, 1990) (dissolved oxygen =
125 $4.07 \pm 0.89 \text{ mg L}^{-1}$; temperature = $27.64 \pm 2.05^\circ\text{C}$; pH = 7.64 ± 0.54 ; and conductivity =
126 $208.29 \pm 97.57\mu\text{S/cm}$). The Ethics Committee for the Use of Animals (ECUA),
127 UNESP/FCAV approved the experimental procedures, under protocol n° 5315/20.

128

129 **2.2. Experimental design**

130

131 The tilapia were randomly distributed in 15 tanks (100L of water, n=5) to compose the
132 following treatments: T0 (control group, not treated with Doxycycline); T1, T2, T3 and T4
133 (treated with 10, 20, 40 and 80mg/kg (bodyweight) of Doxycycline, respectively). Five
134 animals were sampled per treatment in 3 periods, that is, 2, 4 and 8 days (Table 1), to collect
135 blood samples for hemogram and biochemical determination, in addition to organs such as
136 spleen, liver and kidneys (cranial and caudal) for somatic and histopathological evaluation.

137

138 **2.3. Experimental diet**

139

140 The commercial pelleted food, containing 36% crude protein, 12% moisture, 70 g/kg
141 ethereal extract, 140 g/kg mineral matter, 50 g/kg crude fiber, 25 g/kg calcium, 8 g/kg
142 phosphorus and vitamin C 350 mg/kg. (Nutripiscis® - Presence Company) was the option to
143 compose the experimental diets of tilapia. Feeding was performed twice a day (8:00 am and
144 5:00 pm), with administration of 2% of the biomass in the tanks. To prepare the diets, the
145 ration was weighed daily in proportion to the average weight of the tilapia in each tank. Then,
146 Doxycycline (Doxycycline: Sandoz Farmececitic Industry from Brazil Ltd.) was added at
147 doses of 10, 20, 40 and 80mg/kg (bodyweight) and homogenized in 2% of vegetable oil,
148 composing the diets of T1, T2, T3 and T4, respectively. For the standardization of diets and
149 nutritional balance, 2% of vegetable oil was added to the diet of the control group (T0).

150

151 **2.4. Fish anesthesia**

152

153 The tilapia were anesthetized by immersion in an aqueous solution of benzocaine at a ratio
154 of 1:10.000 for blood collection and 1:500 at the time of euthanasia. Benzocaine was diluted
155 in 98° alcohol (0.1 g/mL), making up the volume to 1L (Wedemeyer, 1970). Initially, pre-
156 anesthesia was performed, in which the water level of the tanks was lowered to a volume of
157 10L and was added 0.1g of benzocaine already diluted in 98° alcohol. Soon after, each fish
158 was transferred to a container with 1L of water with 0.1g of benzocaine, both procedures were
159 performed under aeration to minimize the stress caused by handling. As soon as the
160 operculum stopped moving, the fish was removed and blood was collected. Finally, the
161 animal was transferred to another container with 0.5g of benzocaine diluted in 1L of water for
162 euthanasia.

163

164 **2.5. Blood collection and hematological analysis**

165

166 Five fish per treatment (one tank for each treatment), after being anesthetized,
167 approximately three mL of blood samples were collected from the tail vessel of each animal at
168 2, 4 and 8 days post-treatment (DPT), which were aliquoted into two sets: one heparin-coated
169 syringe (5000 IU) and one without heparin, for obtaining plasma and serum, respectively.
170 During the exchange of syringes (with and without heparin), the needle was not removed
171 from the vessel, so no blood was lost. The hemogram was performed using a hemocytometer
172 (Neubauer chamber) and Natt and Herrick (1952) solution in the proportion 1:100 v:v).
173 Hematocrit was determined by the microhematocrit centrifugation technique. And circulating
174 hemoglobin, using Rabkin's reagent for reading at a wavelength of 540nm and the mean
175 corpuscular volume (MCV) values were obtained by calculating $MCV = (HT/HE)*100$ and
176 mean corpuscular hemoglobin concentration (CHCM) by calculating $CHCM = (HG/HT)*100$.
177 Differential leukocyte counts were performed in blood extensions with a count of 200 cells,

178 establishing the percentage of each cell type of interest, after previous staining of the
179 extensions with May-Grünwald Giensa Wright (BELO et al., 2013).

180

181 **2.6. Serum biochemical assessment**

182

183 Blood samples from fish without anticoagulant were centrifuged at 10,000 rpm during 10
184 minutes at 4°C to obtain serum and determine alkaline phosphatase (AF), aspartate
185 aminotransferase (AST), creatinine, albumin, total protein, cholesterol, triglycerides and
186 globulin, using a semiautomatic biochemical analyzer (Model LabQuest® - Bioplus
187 Company) and the glycemia of the fish was determined using the Accu-Chek Performa
188 instrument.

189

190 **2.7. Morphometric and histopathological evaluation of organs**

191

192 After 2, 4 and 8 days of treatment, the tilapia were euthanized by immersion in an aqueous
193 solution of benzocaine (1:500) until the anesthetic plane was deepened and the opercular
194 movements were completely lost. Then, they were weighed and dissected by a ventral
195 longitudinal section, from the anus to the operculum; another from the anus to the head
196 following the lateral line and a third passing through the pectoral fin. This dissection allowed
197 a wide view of all organs. For morphometric evaluation, according to Weibel et al. (1969),
198 liver, caudal kidney and spleen of tilapia were collected, which were weighed to express the
199 hepatic, renal and splenic somatic index, calculated by the formula: Somatic index = organ
200 weight X 100/body weight.

201 For histopathological examinations, were evaluated liver, caudal kidney and spleen.
202 Immediately after collecting a fragment of each organ, they were fixed in 10% formalin and
203 after 24 hours they were transferred to 70% alcohol, being sent for preparation of the pieces in
204 the veterinary pathology laboratory, embedded in paraffin and cuts of 5µm will be stained in

205 hematoxylin and eosin. The reading was done in an optical microscope to determine possible
206 pathological changes.

207

208 **2.8. Statistical analysis**

209

210 The experimental design for clinical safety assessment will be entirely randomized in a 5 x
211 3 factorial scheme (five treatments: 10, 20, 40, 80 and control X three evaluation periods: 2, 4
212 and 8 DPT). Analyzes of variance to compare the different experimental groups were
213 performed using the GLM (General Linear Model) procedure of the SAS program, version
214 9.3 (Statistical Analysis Software, 2012). Significant differences ($P<0.05$) were estimated
215 based on Tukey's test at 95% confidence level.

216

217 **3. RESULTS**

218

219 **3.1. Serum biochemical analysis**

220

221 In the analysis of hepatic cytotoxicity of tilapia treated with doxycycline (Figure 1), no
222 significant changes were observed in serum alkaline phosphatase enzyme activity, however,
223 serum levels of AST were significantly higher ($P<0.05$) in animals treated with 80 mg of
224 doxycycline in the longest period of treatment (8 days), compared to animals treated with the
225 lowest dose (10mg) and control group. This result was also observed over time, in which the
226 treatment with 80 mg increased its values in the later period of treatment.

227 In the evaluation of the hepatic functionality of the treatment with Doxycycline (Figure 2),
228 no significant changes were observed in the serum values of creatinine, total protein,
229 cholesterol, triglycerides and globulin. However, after 4 days of treatment with 80 mg of
230 doxycycline an albumin peak was observed and its values returned to their baseline levels on
231 the eighth day.

232 Glycemia assessment (Figure 3) revealed a decrease after 4 days of treatment in the control
233 group and treated with 10 mg of doxycycline, after 8 days of treatment, this decrease was

234 observed in all groups, except for the one treated with 80 mg of doxycycline that no decrease
235 was observed, remaining constantly high throughout the evaluation period.

236

237 **3.2. Hematological analysis**

238

239 In the hematological evaluation of tilapia treated with doxycycline (Figure 4) no significant
240 changes ($P>0.05$) were observed in hematocrit, MCV, HCM and CHCM values. However, it
241 was observed that after 8 days of treatment there was a significant decrease ($P<0.05$) in serum
242 hemoglobin values in animals treated with 40 and 80 mg of doxycycline compared to animals
243 in the control group. Over time, it was observed that animals treated with 40 mg had a
244 significant decrease in hemoglobin levels and animals treated with 80 mg had an increase in
245 circulating erythrocytes.

246 In the leukocyte evaluation (Figure 5), there were no significant changes ($P\geq 0.05$) in the
247 global leukocyte count between the different treatments. It was observed a significant increase
248 of lymphocytes ($P<0.05$) on the second day after the start of treatment in animals treated with
249 80 mg when compared to fish treated with 20 mg/kg, but both did not show significant
250 variations when compared to control tilapia. The evaluation of treatments over time revealed a
251 decrease in monocytes and neutrophils 4 days after treatment with 80 mg doxycycline, which
252 returned to normal levels after 8 days.

253

254 **3.3. Morphometric analysis**

255

256 In the somatic analysis of spleen, liver and kidney, no significant changes were observed in
257 the animals of the different treatments and the control group (Figure 6).

258

259 **3.4. Histopathological changes**

260

261 The histopathological study of tilapia treated with doxycycline showed changes in the liver
262 with loss of hepatic cord architecture, presence of pyknotic nucleus, hydropic degeneration
263 with necrosis of hepatocytes and hepatic sinusoid dilatation (Figure 7). Such histopathological
264 findings were observed more frequently in animals treated with 80 mg of doxycycline.
265 Histological sections of splenic and renal tissues did not show significant changes when
266 compared to animals in the control group. However, it is worth mentioning that studies that
267 aim to quantify and comparatively analyze the formation of melanomacrophages centers in
268 splenic tissues can help to understand their participation during the body's detoxification
269 process.

270

271 **4. DISCUSSION**

272

273 Under outbreak conditions, the use of drugs in aquaculture is indispensable, however, there
274 are few drugs registered for use in fish, which leads to the indiscriminate use of various
275 chemical substances (Carraschi, 2014). As a result, the study of clinical safety in fish becomes
276 relevant, and this happens through hematological and biochemical tests, in which they are
277 essential parameters to assess the physiological condition of fish (Mahmoud et al. 2018)
278 considering the use of pharmaceutical molecules in pisciculture.

279 In the hematological evaluation of the tilapia treated with doxycycline, no changes were
280 observed in the hematocrit, MCV, HCM and CHCM values, corroborating the findings of
281 Costa et al. (2022), in which the tilapia treated with zileuton did not show any change
282 between the different concentrations of the drug administered during an acute inflammatory
283 reaction caused by *Aeromonas hydrophila*.

284 Hemoglobin can indicate the oxygen content in the blood and under stress conditions
285 anoxia can occur, ceasing the oxidative phosphorylation mechanism, being the alternative
286 pathway of energy synthesis in the body (Ramesh et al., 2018). In the study, higher doses of
287 doxycycline (40 and 80 mg/kg) for eight consecutive days decreased hemoglobin
288 concentration. However, no evidence of anemia was observed, as there was no decrease in the
289 circulating values of red blood cells, as well as in the percentage of hematocrit, discarding the
290 hypothesis that treatment with this tetracycline would have resulted in hemolytic changes.
291 Feng et al. (2017) demonstrated that doxycycline binds to the hydrophobic cavity of bovine
292 hemoglobin through multiple interactions in a mechanism similar to drugs with albumin.
293 Engebretson and Hey-Hadavi (2011) observed a decrease in hemoglobin A1c during chronic
294 treatment with doxycycline for three months in patients with type-2 diabetes. For these
295 authors, tetracyclines can inhibit the glycation of non-enzymatic proteins.

296 Similar effects were observed in tilapia, in which the decrease in circulating hemoglobin
297 values in fish treated with 80 mg of doxycycline after eight days of treatment were
298 significantly related to the increase in blood glucose. The metabolic breakdown of glucose
299 (glycolysis) is an important pathway for ATP production, and its levels may change in the
300 blood when the animal is in high-energy demand, being strongly influenced by
301 catecholamines, glucocorticoids and thyroid hormones (Ramesh et al., 2018). Tilapia treated
302 with 80 mg of doxycycline showed a transient increase in circulating albumin values on the
303 fourth day of treatment, returning to baseline values on the eighth day. Hyperalbuminemia
304 usually occurs when there are changes in fluid-electrolyte balance, as the loss of fluid volume
305 from the plasma extracellular compartment results in hemoconcentration, reflecting an
306 increase in serum albumin, this mechanism is clearly described in mammals (Belo et al.,
307 2012).

308 There are few data on the influence of antibacterials on the biochemical indices of fish
309 serum and those that have been published so far are mainly focused on the effects of
310 oxytetracycline (Bojarski et al., 2020) with little information on the use of doxycycline in
311 fish. In the liver evaluation, tilapia treated with 80 mg of doxycycline eight consecutive days
312 had increased serum AST levels, as observed by Oyeniran et al. (2021) in which fish treated
313 with different antibiotics had higher AST activities compared to the control, suggesting
314 changes in liver cytotoxicity. Bojarski et al. (2020) observed an increase in AST in fish
315 exposed to oxytetracycline, possibly resulting from a transient cytotoxic effect during
316 treatment with this tetracycline. The increase in the metabolic degradation of the drug in
317 hepatocytes can result in the production of free radicals that favor the increase of lipid
318 peroxidation and consequently changes in the permeability of the hepatocyte plasma
319 membrane, which can result in extravasation of this enzyme, as well as in the most severe
320 cases cause cytotoxicity (Belo et al., 2012).

321 The data on the hematological and immunological response in fish after antibiotic
322 treatment are complex, as the results obtained by several authors are likely to depend on the
323 antibiotic dosage, infectious processes and the sensitivity of various fish species (Kondera et
324 al., 2020).

325 Leukocytes play a vital role in the immune system of fish, comprising the cellular element
326 of innate immunity and releasing humoral substances such as cationic antimicrobial peptides,
327 components of the complement system, lectins and cytokines (Do Huu et al., 2016).
328 According to Popal et al. (2017) the change in the level of leukocytes is an indication of
329 activation of the immune response. In the present study, no changes were observed in the
330 number of circulating leukocytes during treatment with this tetracycline, suggesting the low
331 toxicity of doxycycline treatment not resulting in inflammatory changes. The decrease in the
332 number of monocytes and neutrophils on the fourth day after treatment with 80 mg of

333 doxycycline corroborates the findings of Maklakova et al., (2011) in rainbow trout
334 (*Oncorhynchus mykiss*) injected with five doses of 20 mg/kg of oxytetracycline.

335 In the somatic analysis of spleen, liver and kidney, no significant changes were observed in
336 the animals of the different treatments and the control group, these results are in agreement
337 with Moraes (2017), in which there was no difference in relation to the weight of the organ
338 and animal weight in study of the clinical safety of amoxicillin for the treatment of
339 streptococcosis in Nile tilapia, the same result was also observed by Dobšíková et al. (2013)
340 who evaluated oxytetracycline in biometric indices in common carp (*Cyprinus carpio L.*).
341 Such results corroborate the results of erythrocyte, leukocyte and biochemical studies of
342 tilapia, suggesting that the drug has not compromised liver and kidney functions resulting
343 from inflammatory processes in these tissues.

344 All fish in this study, regardless of the treatment received, did not show any behavioral
345 and/or clinical changes such as erratic swimming, lethargy, increased opercular beating, skin
346 damage or loss of appetite during treatment for eight days with doxycycline.

347 Therefore, the results observed as a whole demonstrate the clinical safety of treatment with
348 doxycycline administered orally at doses of 10, 20, 40 and 80 mg/kg (bodyweight), although
349 transient changes in liver functionality were observed after eight days of treatment with the
350 dose of 80mg/kg.

351

352 **5. REFERÊNCIAS BIBLIOGRÁFICAS**

353

354 ARACATI, M., RODRIGUES, L., OLIVEIRA, S., MORAES, A., PRADO, E.,
355 FERNANDES, D., ... BELO, M. Clinical safety of Zafirlukast treatment during acute
356 inflammatory reaction in Nile tilapia (*Oreochromis niloticus*). **Ars Veterinaria**, v. 37, n. 2,
357 p. 67-73, 2021.

- 358 BASSETTI, M.; RUSSO, A.; CARNELUTTI, A.; LA ROSA, A.; RIGHI, E. Antimicrobial
359 resistance and treatment: an unmet clinical safety need. **Expert Opinion on Drug**
360 **Safety**. v. 17, n. 7, p. 669-680, 2018.
- 361 BELO, M.A.A. et al. Haematological response of curimbas *Prochilodus lineatus*, naturally
362 infected with *Neoechinorhynchus curemai*. **Journal of Fish Biology**, v. 82, n. 4, p. 1403-
363 1410, 2013.
- 364 BELO, M.A.A.; MORAES, J. R. E.; SOARES, V. E.; MARTINS, M. L.; BRUM, C. D.;
365 MORAES, F. R. Vitamin C and endogenous cortisol in foreign-body inflammatory
366 response in pacus. **Pesquisa Agropecuária Brasileira** 47, 1015-1021, 2012.
- 367 BOJARSKI, B.; KOT, B.; WITESKA, M. Antibacterials in aquatic environment and their
368 toxicity to fish. **Pharmaceuticals**. v.13, n. 8, p. 189, 2020.
- 369 CARNEIRO, P.C.F.; URBINATI, E.C. Salt as stress response mitigator of matrinxã *Brycon*
370 *cephalus* during transport. **Aquaculture Research**, v.32, p. 297-304, 2001.
- 371 CARRASCHI, S. P.; FLORÊNCIO, T.; IGNÁCIO, N. F.; IKEFUTI, C. V.; CRUZ, C.;
372 RANZANI-PAIVA, M. J. T. Hematological and histopathological assessment of pacu
373 (*Piaractus mesopotamicus*) after treatment of pathogens with veterinary medicinal
374 products. **Comparative Clinical Pathology**. v. 26, n. 1, p. 105-114, 2017.
- 375 COSTA, C.; OLIVEIRA, S.; ARACATI, M.; RODRIGUES, L.; COLTURATO, L.;
376 MONTASSIER, H.; BELO, M. Clinical safety of treatment with zileuton, 5-lox inhibitor,
377 during acute inflammatory reaction in Nile tilapia (*Oreochromis niloticus*). **Ars**
378 **Veterinaria**. v. 38, n. 1, p. 23-30, 2022.
- 379 DO HUU, H.; SANG, H. M.; THUY, N. T. T. Dietary β -glucan improved growth
380 performance, *Vibrio counts*, haematological parameters and stress resistance of pompano
381 fish, *Trachinotus ovatus Linnaeus*, 1758. **Fish & shellfish immunology**. v. 54, p. 402-410,
382 2016.

- 383 DOBŠÍKOVÁ, R.; BLAHOVÁ, J.; MIKULÍKOVÁ, I.; MODRÁ, H.; PRÁŠKOVÁ, E.;
384 SVOBODOVÁ, Z.; ... SIWICKI, A. K. The effect of oyster mushroom β -1.3/1.6-D-glucan
385 and oxytetracycline antibiotic on biometrical, haematological, biochemical, and
386 immunological indices, and histopathological changes in common carp (*Cyprinus carpio*
387 *L.*). **Fish & shellfish immunology**. v. 35, n. 6, p. 1813-1823, 2013.
- 388 ENGBRETSON, S. P.; HEY-HADAVI, J. Sub-antimicrobial doxycycline for periodontitis
389 reduces hemoglobin A1c in subjects with type 2 diabetes: a pilot study. **Pharmacological**
390 **Research**. v. 64, n. 6, p. 624-629, 2011
- 391 FDA (FOOD AND DRUG ADMINISTRATION). Approved aquaculture drugs. New
392 Hampshire: U.S. Food and Drug Administration, 2022. Disponível em:
393 <https://www.fda.gov/animal-veterinary/aquaculture/approved-aquaculture-drugs>
- 394 HOLMES, Natasha E.; CHARLES, Patrick GP. Safety and efficacy review of
395 doxycycline. *Clinical Medicine. Therapeutics*, v. 1, p. CMT. S2035, 2009.
- 396 KONDERA, E., BOJARSKI, B., ŁUGOWSKA, K., KOT, B., & WITESKA, M. Effects of
397 oxytetracycline and gentamicin therapeutic doses on hematological, biochemical and
398 hematopoietic parameters in *Cyprinus carpio Juveniles*. **Animals**. v. 10, n. 12, p. 2278,
399 2020.
- 400 MAHMOUD, S.; HASABELNABY, S.; HAMMAD, S.; SAKR, T. Antiviral nucleoside and
401 nucleotide analogs: a review. **Journal of Advanced Pharmacy Research**. v. 2, n. 2, p. 73-
402 88, 2018.
- 403 MAKLAKOVA, M. E.; KONDRATIEVA, I. A.; MIKHAILOVA, E. S.; STUPIN, R. V.;
404 KHAPCHAEV, S. H.; KASUMYAN, A. O. Effect of antibiotics on immunophysiological
405 status and their taste attractiveness for rainbow trout *Parasalmo (= Oncorhynchus) mykiss*
406 (*Salmoniformes, Salmonidae*). **Journal of Ichthyology**. v. 51, n. 11, p. 1133-1142, 2011.

- 407 MORAES, A. C. Eficácia terapêutica, segurança clínica e ecotoxicológica da amoxicilina por
408 via intramuscular para o tratamento de estreptococose em tilápias do Nilo. 2017. 87f. Tese
409 (Doutorado em Medicina Veterinária) - Universidade Estadual Paulista - FCAV,
410 Jaboticabal, 2017.
- 411 NATT, M.P.; HERRICK, C.A. A new blood diluents for counting the erythrocytes and
412 leucocytes of the chicken. **Poultry Science** v. 31, p. 735-738, 1952.
- 413 OLIVEIRA, S. L.; ARACATI, M. F.; RODRIGUES, L. F.; COSTA, C. C.; CONDE, G.;
414 MORAES, A. C.; MANRIQUE, W. G.; CHARLIE-SILVA, I.; BELO, M. A. A. Clinical
415 safety of zafirlukast treatment during a foreign body inflammatory reaction in Nile tilapias,
416 *Oreochromis niloticus*. **International Journal of Development Research**. v.11, p. 47914-
417 47919, 2021.
- 418 OWENS, J. R.; ROBERT, C.; AMBROSE, P. G. Antimicrobial safety: focus on
419 fluoroquinolones. **Clinical infectious diseases**. v. 41, n. Supplement_2, p. S144-S157,
420 2005.
- 421 OYENIRAN, D. O.; SOGBANMU, T. O.; ADESALU, T. A. Antibiotics, algal evaluations
422 and subacute effects of abattoir wastewater on liver function enzymes, genetic and
423 haematologic biomarkers in the freshwater fish, *Clarias gariepinus*. **Ecotoxicology and
424 environmental safety**. v. 212, p. 111982, 2021.
- 425 POOPAL, R. K.; RAMESH, M.; MARUTHAPPAN, V.; BABU RAJENDRAN, R. Potential
426 effects of low molecular weight phthalate esters (C16H22O4 and C12H14O4) on the
427 freshwater fish *Cyprinus carpio*. **Toxicology research**, v. 6, n. 4, p. 505-520, 2017.
- 428 RAMESH, M.; THILAGAVATHI, T.; RATHIKA, R.; POOPAL, R. K. Antioxidant status,
429 biochemical, and hematological responses in a cultivable fish *Cirrhinus mrigala* exposed
430 to an aquaculture antibiotic Sulfamethazine. **Aquaculture**. v. 491, p. 10-19, 2018.

431 SAS Institute Inc. **SAS/STAT software changes and enhancements through computer**
432 **program**. Release 8.9.3. Cary: SAS Institute, 2012.

433 SMITH, K.; LEYDEN, J. J. Safety of doxycycline and minocycline: a systematic
434 review. **Clinical therapeutics**. v. 27, n. 9, p. 1329-1342, 2005.

435 WEDEMEYER, G. Stress of anesthesia with MS-222 and benzocaine in rainbow trout (*Salmo*
436 *gairdneri*). **Journal of the Fisheries Research Board of Canada**, v.22, n.5, 1970.

437 WEIBEL, E.R.; STAUBLI, W.; GNAGI, H.R.; HESS, F.A. Correlated morphometric and
438 biochemical studies on the liver cell. **Journal of Cell Biology**, p.68-91, 1969.

439

440

441

442

443

444

445

446

447

448

449

450

451

452

453

454

455

456

457

458

459

460

461 **TABLES AND FIGURES:**462 **Table 1.** Distribution of tilapia in different treatments with Doxycycline.

Groups	Treatments	Days after starting Doxycycline treatment		
		2	4	8
T0	Control (not treated with Doxycycline)	N=5	N=5	N=5
T1	Treated com 10 mg/kg de p.v. de Doxicicline	N=5	N=5	N=5
T2	Treated com 20 mg/kg de p.v. de Doxicicline	N=5	N=5	N=5
T3	Treated com 40 mg/kg de p.v. de Doxicicline	N=5	N=5	N=5
T4	Treated com 80 mg/kg de p.v. de Doxicicline	N=5	N=5	N=5

463

464

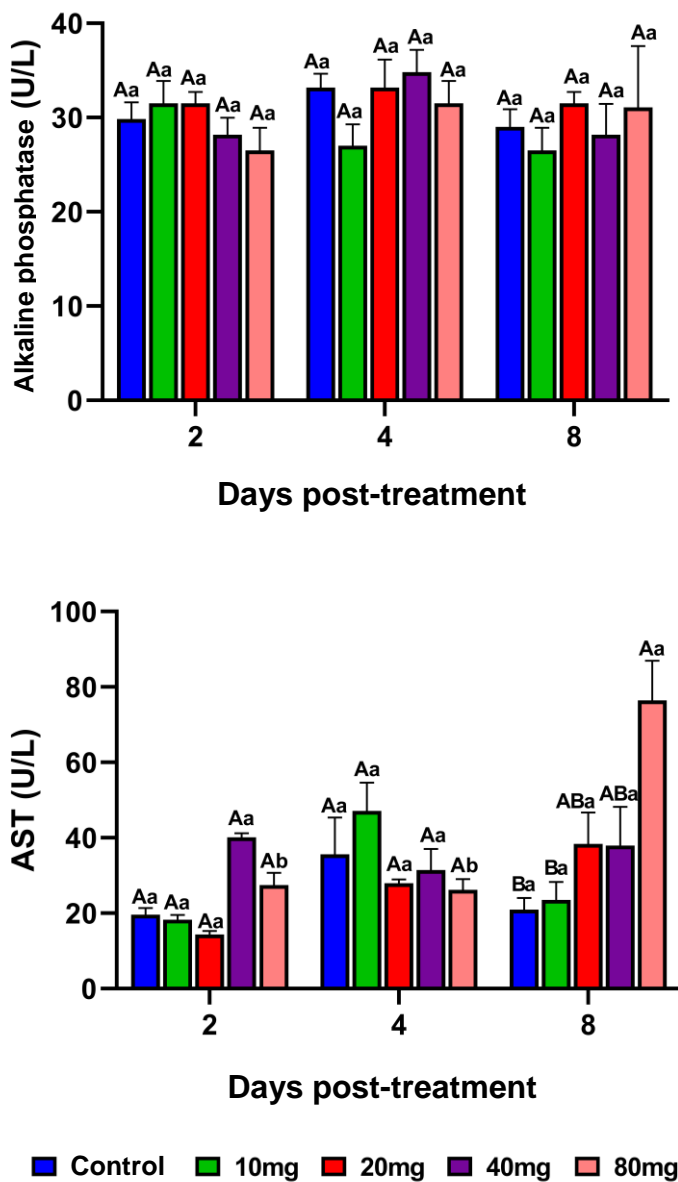


Figure 1. Alkaline phosphatase and aspartate aminotransferase (AST) analysis of tilapia treated with doxycycline. Means (n=5) followed by the same letter do not differ by Tukey's test (P<0.05). Capital letters compare the different treatments within each experimental day, lowercase letters compare the evolution of each treatment between the different experimental days.

465

466

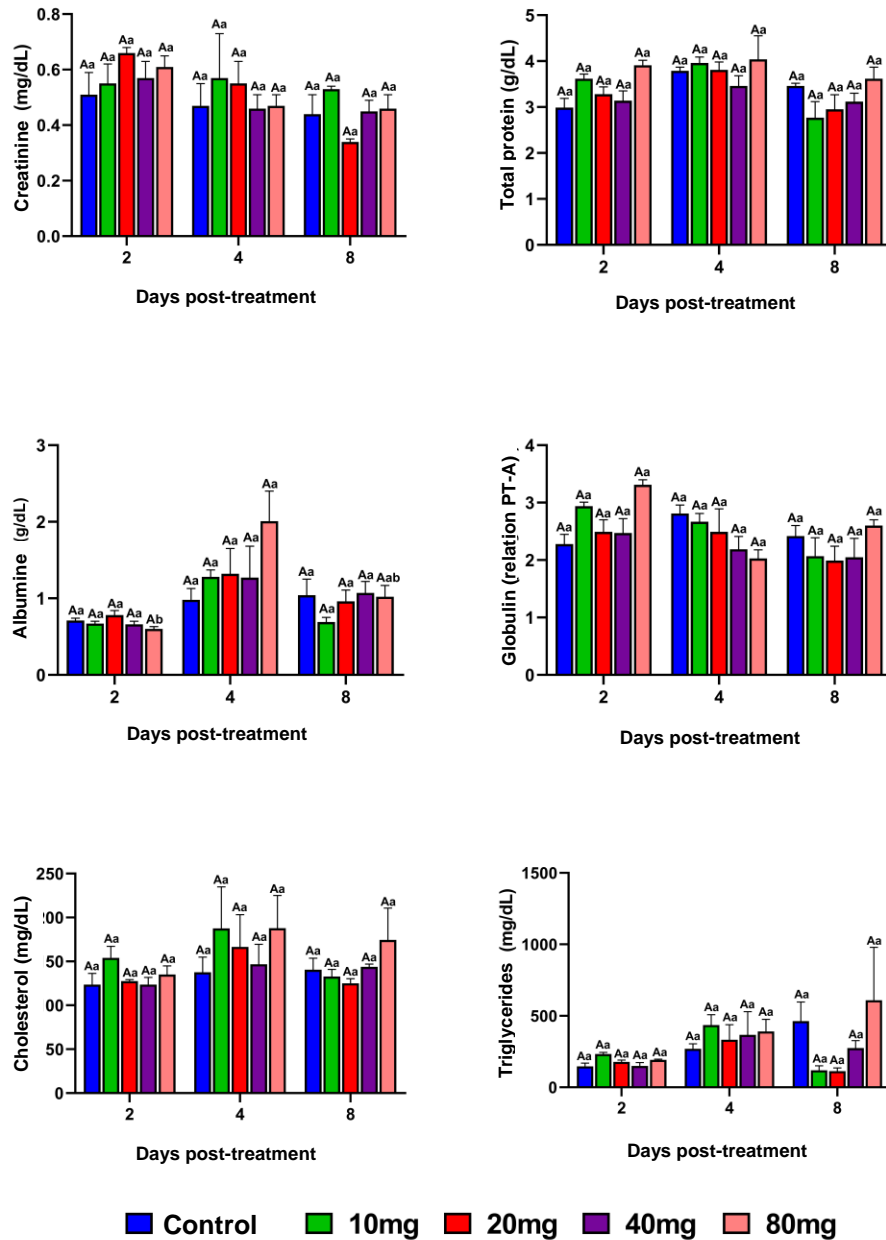


Figure 2. Analysis of creatinine, total protein, albumin, globulin, cholesterol and triglycerides of tilapia treated with doxycycline. Means (n=5) followed by the same letter do not differ by Tukey's test ($P < 0.05$). Capital letters compare the different treatments within each experimental day, lowercase letters compare the evolution of each treatment between the different experimental days.

467

468

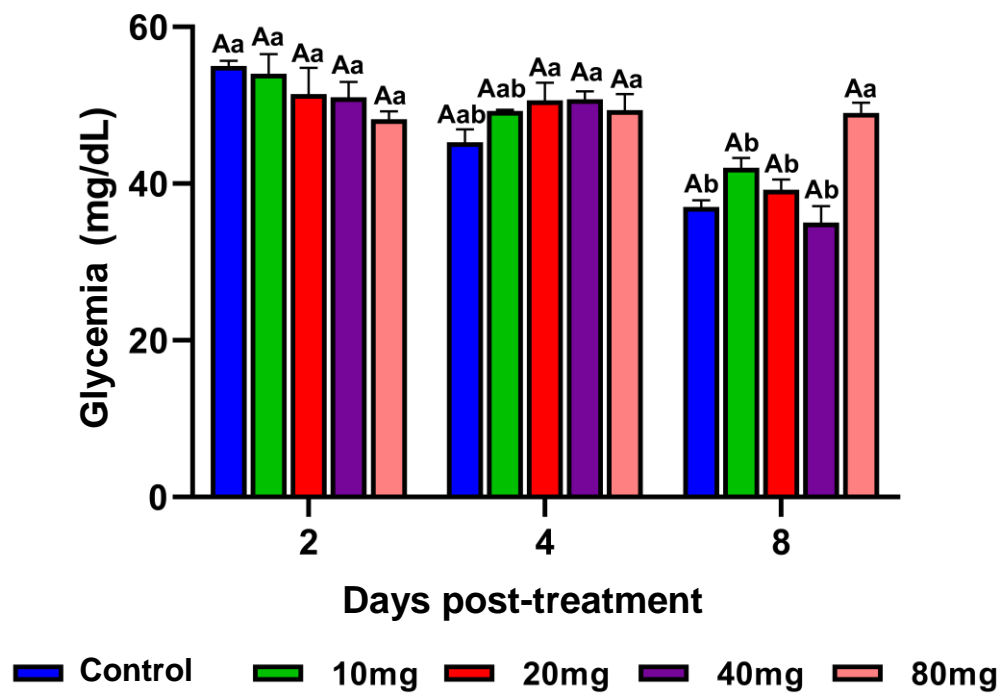


Figure 3. Analysis of blood glucose in tilapia treated with doxycycline. Means (n=5) followed by the same letter do not differ by Tukey's test ($P < 0.05$). Capital letters compare the different treatments within each experimental day, lowercase letters compare the evolution of each treatment between the different experimental days.

469

470

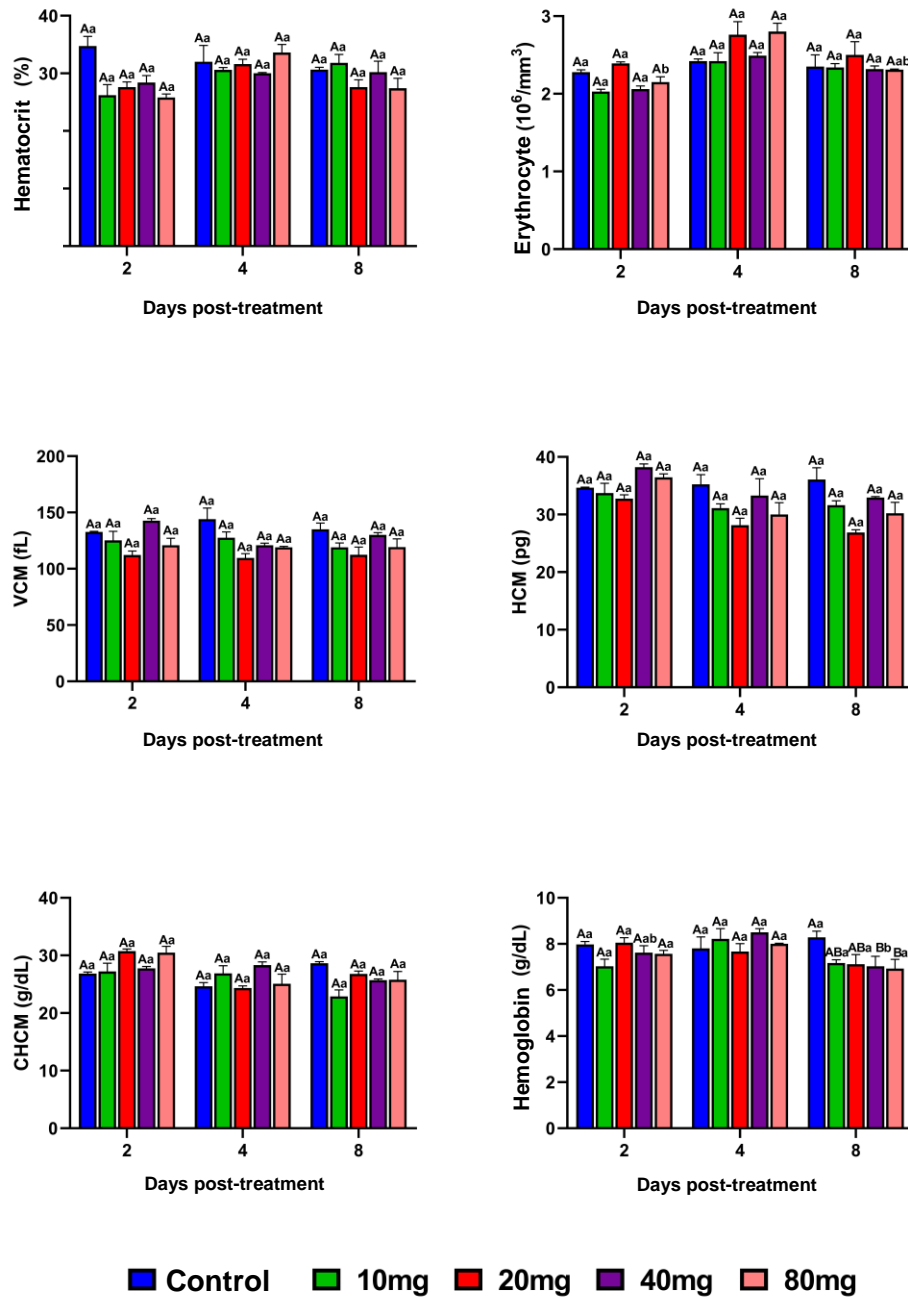


Figure 4. Hematological analysis of tilapia treated with Doxycycline. Means (n=5) followed by the same letter do not differ by Tukey's test ($P < 0.05$). Capital letters compare the different treatments within each experimental day, lowercase letters compare the evolution of each treatment between the different experimental days.

471

472

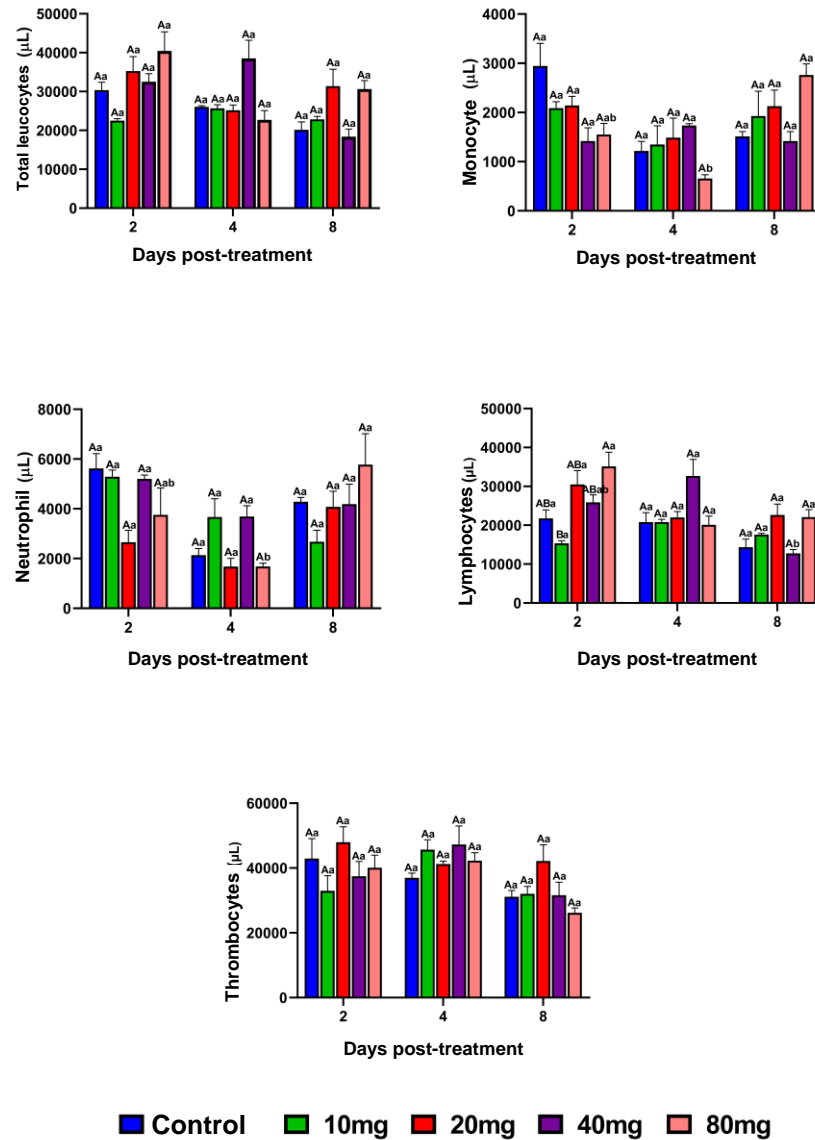


Figure 5. Leukocyte analysis of tilapia treated with Doxycycline. Means (n=5) followed by the same letter do not differ by Tukey's test ($P < 0.05$). Capital letters compare the different treatments within each experimental day, lowercase letters compare the evolution of each treatment between the different experimental days.

473

474

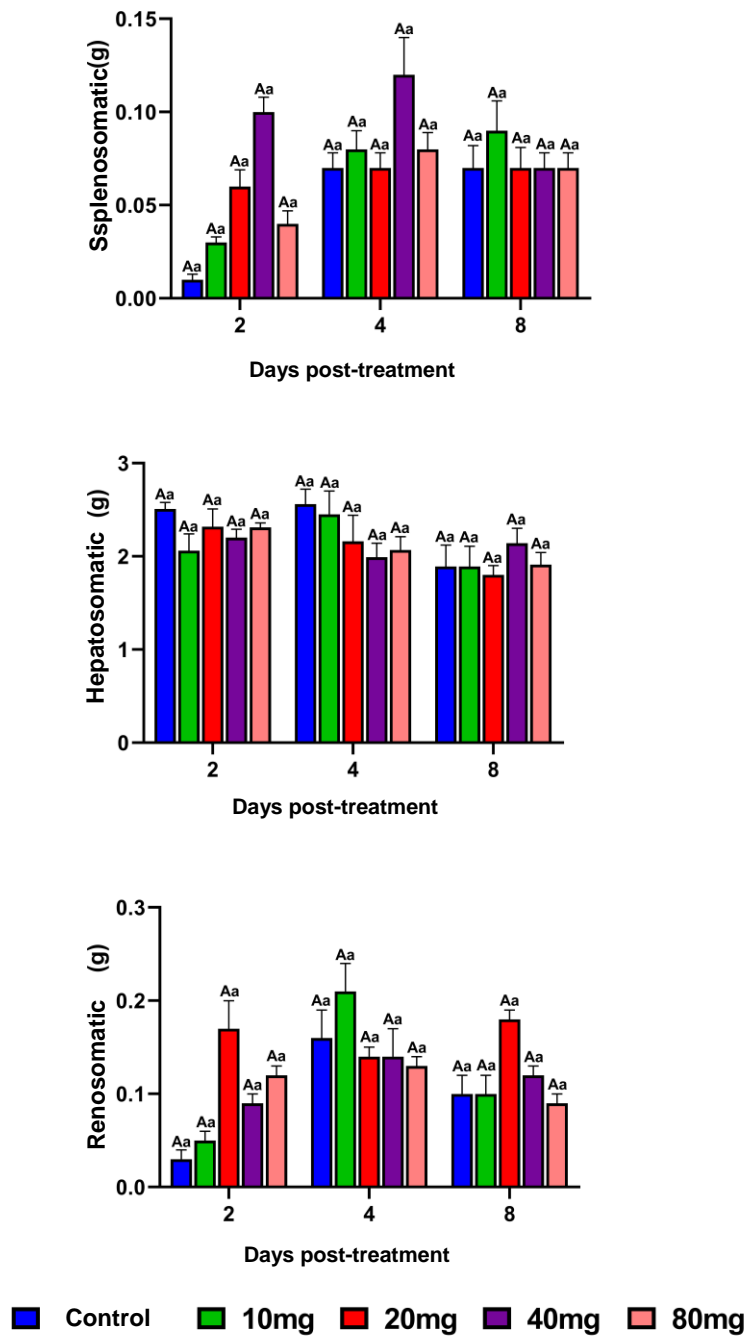


Figure 6. Somatic evaluation of spleen, liver and kidney of tilapia treated with Doxycycline. Means (n=5) followed by the same letter do not differ by Tukey's test ($P < 0.05$). Capital letters compare the different treatments within each experimental day, lowercase letters compare the evolution of each treatment between the different experimental days.

475

476

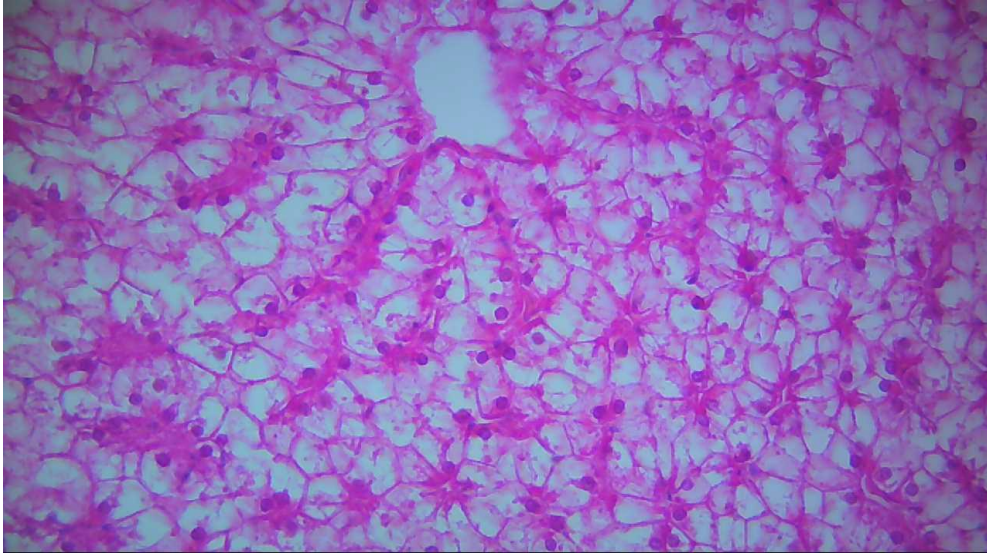

Figure 7. Photomicrograph of histological section of the liver of tilapia treated with doxycycline. Loss of architecture of the hepatic cords, presence of pyknotic nuclei, hydropic degeneration with necrosis of hepatocytes and hepatic sinusoid dilatation are observed. H.E stain, 40x magnification.