

# RADIOGRAPHIC AND DENSITOMETRIC ASPECTS OF EXPERIMENTAL RADIAL FRACTURES OF DOGS TREATED WITH PLATELET-RICH PLASMA

## ASPECTOS RADIOGRÁFICOS E DENSITOMÉTRICOS DE FRATURAS EXPERIMENTAIS DO RÁDIO DE CÃES TRATADAS COM PLASMA RICO EM PLAQUETAS

T. F. B. SOUZA<sup>1</sup>, G. T. N. M. FERREIRA<sup>1</sup>, S. S. SAKAMOTO<sup>1</sup>,  
V. B. ALBUQUERQUE<sup>1</sup>, S. R. M. BOMFIM<sup>1</sup>, A. L. ANDRADE<sup>1\*</sup>.

### SUMMARY

The present article aimed to assess bone healing of experimental radial fractures, treated or not with autologous PRP (platelet-rich plasma), by means of radiographic and densitometric studies. Eleven dogs were randomly allocated in two experimental groups: control group (CG n=6) and PRP group (PRPG n=5). All dogs underwent radial osteotomy and osteosynthesis (external skeletal fixation) of the right forelimb, in which a 2.0 mm defect was created. The gap was filled with PRP in the treated group (PRPG); while CG received no treatment. Radiographic and densitometric studies were performed immediately at the end the procedure and 14, 21, 28, 35, 45 and 60 days after the surgery (M0, M14, M21, M28, M35, M45 e M60). Statistical analysis was performed using analysis of variance with repeated measures (ANOVA) followed by Tukey test to compare means Friedman and Dunn post hoc tests to compare times within each group; and Mann-Whitney to compare groups at all times ( $p<0.05$ ). Regarding time, radiographic scores and densitometric values changed significantly from moment 0 to moment 60 within the PRPG. The comparison of the two groups shows that radiographic scores changed significantly from M28 and densitometric values from M45 and M60. It can be concluded that under the conditions of this study; PRP can be used as an adjuvant therapy to promote bone healing of experimental radial fractures (gap 2.0 mm) of dogs treated with external skeletal fixation.

**KEY-WORDS:** Transforming growth factor beta. Blood platelets. Bone and bones.

### RESUMO

O presente artigo teve como objetivo avaliar a cicatrização óssea de fraturas experimentais do rádio de cães, tratadas ou não com o PRP autógeno, por meio de estudos radiográfico e densitométrico. Foram utilizados 11 cães, alocados aleatoriamente em dois grupos experimentais: o grupo controle (G-controle, n=6) e o grupo PRP (G-PRP, n=5). Todos os animais foram submetidos à osteotomia e osteossíntese (fixador esquelético externo) do rádio direito, gerando-se um *gap* de 2mm, que foi preenchido com PRP apenas no grupo G-PRP. Os estudos radiográficos e densitométricos foram realizados no pós-operatório imediato e aos 14, 21, 28, 35, 45 e 60 dias de pós-operatório (M0, M14, M21, M28, M35, M45 e M60). A análise estatística foi realizada por meio da Análise de Variância com Medidas repetidas (ANOVA) e teste de Tukey para comparação de médias; teste de Friedman seguido do teste de Dunn para comparar os momentos em cada grupo e o teste de Mann-whitney para comparar os grupos em cada momento ( $p<0,05$ ). Referente à avaliação entre os momentos houve diferença significativa entre M0 e M60 nas avaliações radiográficas e densitométricas dentro do grupo G-PRP. Na comparação entre os dois grupos houve diferença estatística na avaliação radiográfica a partir de M28; e na avaliação densitométrica nos momentos M45 e M60. Conclui-se, nas condições deste estudo, que o PRP pode ser utilizado como terapia adjuvante, pois promove cicatrização óssea precoce em fraturas experimentais (*gap* de 2,0 mm) do rádio de cães tratadas com fixador esquelético externo.

**PALAVRAS-CHAVE:** Fator transformador de crescimento beta. Plaquetas. Osso e ossos.

<sup>1</sup> Departamento de Clínica, Cirurgia e Reprodução Animal. Curso de Medicina Veterinária da Faculdade de Odontologia (FOA). Universidade Estadual Paulista (Unesp). \* corresponding author: landrade@fmva.unesp.br. Rua Clóvis Pestana, 793, prédio 87, Araçatuba-SP. CEP. 16050-680, Brasil.

## INTRODUCTION

The healing of fractures with bone defects, in poorly vascularized areas, is difficult and classical techniques of stabilization and bone grafting does not always provide satisfactory results, which results in delayed bone healing or non healing at all (JACKSON & MILLIS, 2007, BOUDRIEAU, 2007).

Besides the correct fixation method, biological materials such as bone morphogenetic proteins, bone marrow, stem cells, platelet-rich plasma, among others are used in order to accelerate the bone healing process and minimize complications (MARX, 2004, BOUDRIEAU, 2007, JACKSON & MILLIS, 2007).

The plasma rich in platelets (PRP) is an autologous concentration of platelets in a small volume of plasma obtained by centrifuging the whole blood. It is rich in growth factors (GF) and osteoconductive proteins (fibrin, fibronectin and vitronectin), which serve as a matrix for cell migration, promoting osteoconduction, epithelialization and osteointegration (OBARRIO et al., 2000, HENDERSON et al., 2003, MARX, 2004). PRP to be efficient should have 338% minimal increment of the basal value of the platelet count (MARX et al., 1998).

PRP increases mainly the concentration of growth factors derived from platelets (PDGFs – aa, bb, ab), transforming growth factor  $\beta$  (TGF-  $\beta$ 1 and  $\beta$ 2), vascular endothelial growth factor (VEGF) and epidermal growth factor (EGF), which are present in the  $\alpha$  granules of platelets (MARX, 2001, SANCHEZ, 2003, WROTNIAC et al., 2007). PDGF and TGF-  $\beta$  were demonstrated in the human autologous by immunostaining. Osteoprogenitor and stem cells obtained from bone marrow in bone graft with medullary portion, were stained with antibodies of membrane receptors to PDGFs and TGF-  $\beta$ ; thus confirming that they act on the repair of bone tissue (MARX et al., 1998).

GF stimulate angiogenesis and proliferation of fibroblasts, causing an increase of collagen synthesis. Studies have shown that the use of PRP alone or combined with other types of graft, shortens the time required for bone healing (MARX 2004, GERARD et al. 2006, WROTNIAC et al. 2007).

This study aimed to evaluate the bone healing of experimental radial fractures of dogs in the presence or not of autologous PRP using radiography and densitometry.

## MATERIAL AND METHODS

The study was conducted on the premisses of the Curso de Medicina Veterinaria of Faculdade de Odontologia, UNESP, in Araçatuba, SP. The study was duly approved by the Ethics Council in Animal Experimentation, following recommendations of COBEA under protocol 2007-008690.

Eleven mongrel dogs, male and castrated female, aged between 1 and 5 years, and weighing from 4 to 6 ponds from the Control Center of Zoonoses, Sao Paulo, were used. After an adjustment period in the kennels of the institution, a clinical assessment (leishmaniasis

serology, complete blood and platelet counts) were carried out. The dogs were treated for worms, vaccinated and kept on a repellent leash (Scalibor<sup>®</sup>) and treated with ectoparasiticide (Fipronil) monthly, in order to prevent the occurrence of concomitant diseases that could interfere with the experiment.

Two experimental groups were randomly constituted: control group (control-G) with six dogs and PRP group (PRP-G) with five dogs. All dogs underwent transverse osteotomy across the circumference of the right radius leading to an overall gap of 2 mm, in order to promote a bone defect and to mimic a clinical situation of a fracture with delayed bone healing. Then, stabilization of the fracture was performed through bilateral uniplanar external skeletal fixation pins of 1.5 mm (Cäomédica<sup>®</sup>). The dogs of PRP-G had their bone fracture filled with 1.0 mL of PRP gel, which was previously processed in the laboratory; while in the control-G the gap remained empty.

For the osteotomy and osteosynthesis, the dogs were submitted to food and water fasting for 12 and 2 hours, respectively. Intramuscular morphine hydrochloride (0.5 mg/kg) and Midazolam (0.2 mg/kg) were used as pre-anesthesia, followed by intravenous Propofol (4 mg/kg) associated to Midazolam (0.2 mg/kg). They were kept under inhalation anesthesia with isoflurane in semi-closed circuit with initial vaporization 3V% that varied during the procedure according to individual requirement. Also, brachial plexus was blocked (total volume was based on a 7 mg/kg dose of lidocaine split 1:1 with bupivacaine, both with epinephrine) (TRANQUILLI et al., 2007). Concomitantly, intravenous antibiotics (Cefalotina 30 mg/kg) was administered for prophylaxis of infection.

After 15 minutes from the pre-anesthesia, 8.0 mL of blood was collected by jugular venipuncture in a tube containing 2.0 mL of the anticoagulant sodium citrate, in order to prepare the autologous PRP. A blood aliquot was separated for platelet total count, and the remainder underwent the first centrifugation (160 G/20 minutes). Next, all the supernatant together with leukocytes plus 2 mm of erythrocytes were transferred to another tube for the second centrifugation (400 G/15 minutes), yielding 1.0 mL of PRP. In order to assure the minimum increment of 338% from the baseline, another platelet count was performed. At the moment of use, 10% of calcium chloride was added to PRP in a hot water bath for gelification and activation, which was then ready to be used.

Trichotomy and antisepsis were performed, followed by surgical approach by medial access of the right radius until the diaphysis was visualized for total osteotomy, according to Piermattei & Flo (1999). The fracture was carried out using a diamond disk attached to low speed pen, leaving a 2.0 mm gap, which was filled in a double-blind scheme with PRP in the dogs from the PRP-G. At the same time, the external fixator was applied followed by surgical dressings.

At the end of surgery, brachial plexus block was repeated for analgesic supplementation. In the post-operative, morphine chloridrate (0.5 mg/kg, SC every 4 hours during the first 12 hours), followed by Tramadol

chloridrate (4 mg/kg every 8 hours, during 5 days), and Meloxicam (0.2 mg/kg every 24 hours, during 3 days) were administered to promote analgesia. As well as antibiotics treatment with Cefalexina (30 mg/kg every 12 hours, during 10 days) and daily dressings until implant removal, when the dogs could be adopted.

Immediately after surgery, radiographic and densitometric exams were performed and on the 14, 21, 28, 35, 45 and 60 days post-surgery (M0, M14, M21, M28, M35, M45 and M60). Radiography was made with an aluminum ladder placed parallel to the radio and then scanned. Densitometry values (mmAl) were obtained by image analysis using the computer program Imaje J<sup>®</sup> (LOUZADA et al., 2001). For radiographic evaluation, the modified score according to Wilson et al. (2006) was used: (0) fracture line from 1.0 to 2.0 mm without bone proliferation; (1) fracture line from 1.0 to 2.0 mm, with bone proliferation, without bridging callus; (2) fracture line from 1.0 to 2.0 mm, with bone proliferation and bridging callus; (3) fracture line < 1.0 mm, without bone proliferation; (4) fracture line < 1.0 mm, with bone proliferation, without bridging callus; (5) fracture line < 1.0 mm, with bone proliferation and bridging callus (clinical healing) and (6) absence of fracture line.

Statistical analysis was performed using analysis of variance with repeated measures (ANOVA) and Tukey test to compare means, followed by Friedman and Dunn tests to compare times within each group and Mann-Whitney test to compare the groups at all times, at a 5% significance level, using SAS (Statistical Analysis System).

## RESULTS AND DISCUSSION

For every dog, the minimum increment of 338% from the baseline was reached as recommended by

Marx et al. (1998) (Table 1). Thus showing that the methodology to prepare PRP was effective, which corroborates Dias et al. (2002) and Oyama et al. (2004) who used similar procedure. A common laboratory centrifuge and a routinely clinical procedure were used, different than Obarrio et al. (2000) and Marx (2004), who used expensive equipment.

PRP activation and gelification were appropriately conducted using 10% calcium chloride as described by Wilson et al. (2006). This procedure did not cause local and systemic adverse reactions as reported by Sanchez et al. (2003), who used bovine thrombin and observed the development of antibodies against clotting factors. Silva et al. (2009) while using calcium chloride and tromboplastin (soluplastin<sup>®</sup>) also observed development of foreign body reactions that might have negatively influenced the action of PRP. Barbosa et al. (2008) used soluplastin<sup>®</sup> without adverse reaction.

PRP preparation occurred simultaneously with the surgical procedure to ensure that it was going to be used soon after being prepared, since three hours after the centrifugation only PDGF keeps its concentration, while TGF-beta decreases considerably (RUTKOWSKI, et al. 2008).

Radiographic evaluation results were significantly different among groups from the 28<sup>th</sup> day post-surgery (M28) (Table 2). This result agrees with Wilson et al. (2006), who also reported a difference between the control group and PRP treated group while studying bone fractures in rabbits. On the other hand, Marx et al. (1998) in a study of mandibular reconstruction and Silva et al. (2007) who evaluated the use of PRP associated with hydroxyapatite in radial bone defects of dogs set with plates and screws, did not report statistical difference among control and PRP treated groups.

**Table 1** – Basal platelet counts and final PRP of dogs in the treated group (PRP-G), and percent concentration.

Dog	Platelet count/ $\mu$ L of the treated group (PRP-G)		
	Basal	PRP	Concentration
1	202,500	875,000	432%
2	275,000	1,445,000	525%
3	172,500	1,082,500	628%
4	187,500	1,540,000	821%
5	310,000	1,047,500	338%

PRP=Platelet-Rich Plasma

**Table 2** – Maximum, minimum and mean values of the radiographic scores (0-6) of dog radius, grouped according to the day of evaluation.

Time (days)	control-G		PRP-G	
	Mean	Min – Max	Mean	Min – Max
M0	0b	0 – 0	0 b	0 – 0
M14	1.5	0 – 3	3 b	0 – 3
M21	3 <sup>a</sup>	1 – 4	3	1 – 4
M28	1 B	1 – 3	4 A	1 – 4
M35	1 B	1 – 3	4 A	4 – 4
M45	1 B	1 – 4	4 A	4 – 4
M60	1 B	1 – 5	5 aA	4 – 5

Means followed by different letters, lowercase in the column and uppercase in the row, are significantly different by Tukey test (P<0.05).

**Table 3** - Mean ( $\bar{X}$ ) and standard deviation of densitometric values, in mmAL, of dog radius according to the time of evaluation.

Time (days)	Densitometric values ( $\bar{X} \pm SD$ )	
	control-G	PRP-G
M0	5.04 $\pm$ 0.42	5.18 $\pm$ 0.21 b
M14	5.69 $\pm$ 0.23	5.54 $\pm$ 0.15 b
M21	5.27 $\pm$ 0.24	5.54 $\pm$ 0.22 b
M28	5.44 $\pm$ 0.19	5.56 $\pm$ 0.14 b
M35	5.16 $\pm$ 0.25	5.80 $\pm$ 0.34
M45	5.28 $\pm$ 0.13 B	5.84 $\pm$ 0.09 A
M60	5.19 $\pm$ 0.19 B	6.41 $\pm$ 0.18 aA

Means followed by different letters, lowercase in the column and uppercase in the row, are significantly different by Tukey test ( $P < 0.05$ ).

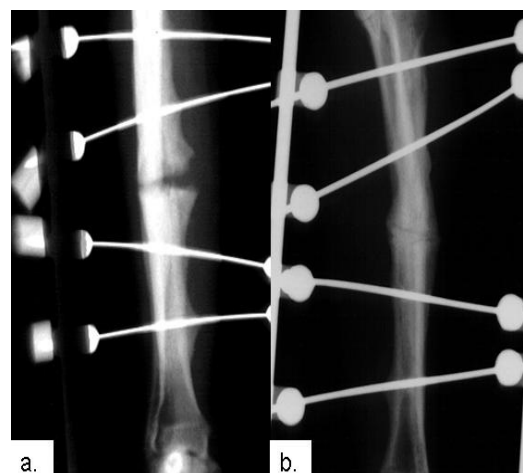
The external fixation method used allowed greater formation of periosteal callus and probably more micro-movements when compared to plates and screws (PIERMATTEI & FLO, 1999), which explains the radiographic appearance of the radius from control-G that showed an increased gap of the fracture line over time, after surgery. Probably, the blood vessels were not sufficient in number and organization to promote a stable and oxygenated environment to allow differentiation of osteoblasts and maintenance of osteocytes to promote healing. Thus, there was re-absorption away from the fracture site that characterizes a delayed bone healing. However, in the PRP-G, a continuous reduction of the fracture line was observed, with organization and union of bone callus, which indicates that PRP increased vascularity and cellularity allowing early deposition of the mineral matrix.

From the subjective evaluation of radiographic imaging, 80% (4/5) of the dogs treated reached clinical healing with greater radiopacity (Figure 1), which differs from Silva et al. (2009) who reported similar results between the control and PRP groups when treating bone fractures in rabbit skulls. The discrepant results are probably due to differences in bone healing processes, since fractured skull bones heal through a slower process and without the formation of bone callus.

The densitometric evaluation displayed a statistically different result between the groups in M45 and M60 (Table 3). On the other hand, Silva et al. (2007) did not observe difference among groups even 60 days after surgery. However, the fixation method used (plate and screws) was different from the method adopted here, which is known to promote a longer healing time without periosteal callus. Therefore, the fixation method chosen may have influenced the results.

Similar to the results from the radiographic evaluation, densitometric results were not significantly different over time in the control-G, but it was significantly different between M0 and M60 in the PRP-G, thus showing that PRP increased bone deposition at the fracture and bone mineral density. Silva et al. (2007) also reported higher bone mass density in the treated group after 45 days, but without statistical significance.

The better healing process displayed by the PRP-G compared to control-G was, probably, due to an earlier and more intense vascularization in the presence of growth factors, which were able to promote cellular proliferation in the fracture site, thus accelerating the deposition of bone matrix that lead to clinical union in 80% (4/5) of the dogs after 60 days even in experimental fractures with a 2.0 mm gap.



**Figure 1 (a.)** - Radiographic image of a dog in the control-G 60 days after surgery (M60) with a visible periosteal proliferation fracture line without bridging callus and re-absorption area in the fracture line; (b.) radiographic image of a dog in the PRP-G 60 days after surgery (M60) with a discreet fracture line and bridging callus (clinical union).

## CONCLUSION

From the results presented, Platelet-Rich Plasma can be used as adjuvant therapy, once it promoted early bone healing of experimental radial fractures (with a 2.0 mm gap) in dogs treated with external skeletal fixation.

## ACKNOWLEDGMENTS

We are thankful to Profs. Silvia H. V. Perri and Mario J. Q. Louzada for helping us with the statistical analysis and bone densitometry, respectively. To my parents and Fundação para o Desenvolvimento da Unesp (FUNDUNESP) for the financial support and to Fundação de Amparo à Pesquisa do Estado de São Paulo (FAPESP) for the grant.

## REFERENCES

BARBOSA, A. L. T., DEL CARLO, R. J., GOMES, H. C., OLIVEIRA, A. C., MONTEIRO, B. S., DEL CARLO, B. N. Plasma rico em plaquetas para reparação de falhas ósseas em cães. **Ciência Rural**, v.38, n.5, p.1335-1340, 2008.

BOUDRIEAU, R. J. Fraturas do rádio e da ulna, In: SLATTER, D. **Manual de cirurgia de pequenos animais**. Vol.2. 3.ed. São Paulo: Manole, 2007. p.1953-1973.

DIAS, E. C. L. C. M., BARROS, M. A. A., ANDRADE, R. Plasma Rico em Plaquetas. RBP: **Revista Brasileira de Implantodontia Prótese Sobre Implante**, v.8, n.3, p.36-38, 2002.

GERARD, D., CARLSON, E. R., GOTCHER, J. E., JACOBS, M. Effects of platelet-rich plasma on the healing of autologous bone grafted mandibular defects in dog. **Journal of Oral and Maxillofacial Surgery**, v.64, n3, p.443-451, 2006.

HENDERSON, J. L., CUPP, C. L., ROSS, E. V., SHICK, P. C., KEEFE, M. A., WESTER, D. C., HANNON, T., MCCONNELL, D. The effects of autologous platelet gel on wound healing. **Ear, Nose and Throat Journal**, v.82, n.8, p.598-602, 2003.

JACKSON, A. M., MILLIS, D. L. Uniões tardias, não-uniões e má-uniões. In: SLATTER, D. **Manual de cirurgia de pequenos animais**. Vol.2. 3.ed. São Paulo: Manole, 2007. p. 1849-161.

LOUZADA, M. J. Q., NOGUEIRA, G. P., GARCIA JUNIOR, I. R., CARVALHO, C. A., PAULA, G. A. Densitometria óptica radiográfica em análise de densidade óssea de mandíbulas de coelhos castrados. **FOL Faculdade de Odontologia de Lins/UNIMEP**, v.13, n.1, p.33-38, 2001.

MARX, R. E., CARLSON, E. R., EICHSTAEDT, R. M., SCHIMMELE, S. R., STRAUSS, J. E., GEORGEFF, K. R. Platelet-rich plasma: growth factor

enhancement for bone grafts. **Oral Surgery Oral Medicine Oral Pathology Oral Radiology and Endodontics**, v.85, n.6, p.638-646, 1998.

MARX, R. E. Platelet-rich plasma: evidence to support its use. **Journal Oral Maxillofacial Surgery**, v.62, n.4, p.489-496, 2004.

MARX, R. E. Platelet-rich plasma (PRP): what is PRP and what is not PRP? **Implant Dentistry**, v.10, n.4, p.225-228, 2001.

OBARRIO, J. J., ARAÚZ-DUTARI, J. I., CHAMBERLAIN, T. D., CROSTON, A. The use of autologous growth factors in periodontal surgical therapy: platelet gel biotechnology: case reports. **International Journal of Periodontics & Restorative Dentistry**, v.20, n.5, p.487-497, 2000.

OYAMA, T., NISHOMOTO, S. TSUGAWA, T., SHIMIZU, F. Efficacy of platelet-rich plasma in alveolar bone grafting. **American Association of Oral and Maxillofacial Surgeons**. v.62, p.555-558, 2004.

PIERMATTEI, D. L., FLO G. L. **Manual de ortopedia e tratamento das fraturas dos pequenos animais**. 3.ed. São Paulo: Manole, 1999. 694p.

RUTKOWSKI, J. L., THOMAS, J. M., BERING, C. L., SPEICHER, J. L., RADIO, N. M., SMITH, D. M., JOHNSON, D. A. An Analysis of a rapid, simple, and inexpensive technique used to obtain platelet-rich plasma for use in clinical practice. **Journal of Oral Implantology**, v.34, n.1, p.25-33, 2008.

SANCHEZ, A. R., SHERIDAN, P. J., KUPP, L. I. Is platelet-rich plasma the perfect enhancement factor? Current Review. **The international journal of oral and maxillofacial implants**, v.18, n.1, p.93-103, 2003.

SILVA, P. S. A., DEL CARLO, R. J., SERAKIDES, R., MONTEIRO, B. S., BALBINOT, P. Z., ELEOTÉRIO, R. B., PAEZ, O. L. A., VILORIA, M. I. V. Plasma rico em plaquetas associado ou não ao osso esponjoso autógeno no reparo de falhas ósseas experimentais. **Ciência Rural**, v.39, n.1, p.129-134, 2009.

SILVA, S., B., FEERIGNO, C. R. A., ATERMAN, F. A., BACCARIN, D. C. B. B., YASBEK, K. V., MURAMOTO, C., AMAKU, M. Plasma rico em plaquetas combinado a hidroxiapatita na formação de calo ósseo em fraturas induzidas experimentalmente no radio de cães. **Ciência Rural**, Santa Maria. v.37, n.4, p.1045-1051, 2007.

TRANQUILLI, W. J., THURMON, J. C., GRIMM, K. A. **Lumb & Jones' veterinary anesthesia and analgesia**. 4.ed. Australia: Blackwell. 2007. 1096p.

WILSON, L. M. T., BARBIERI, C. H., MAZZER, N. Estimulação da cicatrização óssea pelo plasma autógeno rico em plaquetas. Estudo experimental em coelhos. **Acta Ortopédica Brasileira**, v.14, n.4, p.208-212, 2006.

WROTNIAK, M., BIELECKI, T., GAZDZIK, T. S.  
Current opinion about using the platelet-rich gel in  
orthopaedics and trauma surgery. **Ortopedia  
Traumatologia Rehabilitacja**, v.9, n.3, p.227-238,  
2007.