

SHORT COMMUNICATION

MUCOPOLYSACCHARIDOSIS IN DOG – REPORT OF TWO CASES

MUCOPOLISSACARIDOSE EM CÃO – RELATO DE DOIS CASOS

M. V. BAHR ARIAS^{1*}, R. A. MARCASSO², S. RASKIN³, S. C. BEGO⁴, M. G. BURIN⁵

SUMMARY

Mucopolysaccharidosis are a group of inherited lysosomal storage disorders caused by deficiency of lysosomal hydrolases needed for the stepwise degradation of glycosaminoglycans. In this report we describe two cases of mucopolysaccharidosis in dogs. A two-month-old male Pitbull was referred with difficulty in locomotion in four limbs and swelling in joints. Clinical examination showed increasing volume of articulations, bad limb angulations with ambulation difficulties and *pectus cavinatum*. Radiographical exams of the skeletal system showed *dysostosis multiplex*. The other dog was an eight-month-old female Rottweiler that was referred due to progressive difficulty in walking. Clinical examination showed tetraplegia, corneal opacities, enlarged tongue and skull deformities. For screening mucopolysaccharidosis, a qualitative and quantitative measurement of urinary glycosaminoglycans and plasma enzymatic assays to evaluate the activity of lysosomal enzymes were made in both dogs. Despite the confirmation of mucopolysaccharidosis with the screening tests, the type between II and VI could not be distinguished.

KEY-WORDS: Dogs. Lysosomal storage diseases. Glycosaminoglycans.

RESUMO

Mucopolissacaridoses são um grupo de afecções hereditárias do armazenamento lisossomal, causada por deficiência de hidrolases lisossomais, necessárias para a degradação das glicosaminoglicanas. Neste relato são escritos dois casos de mucopolissacaridose em cães: Um cão macho, Pitbull, de 60 dias, foi atendido devido à dificuldade de locomoção com os quatro membros e aumento de volume articular. No exame clínico constatou-se aumento de volume e deformidades em articulações e *pectus cavinatum*. Nas radiografias do sistema esquelético observou-se *disostose multiplex*. O outro paciente, uma canina fêmea, Rottweiler, de oito meses, foi atendida devido à dificuldade progressiva de locomoção. No exame clínico constatou-se tetraplegia, opacidade corneal, aumento de volume em língua e deformidade em crânio. Para triagem de mucopolissacaridose, realizou-se na urina dosagem qualitativa e quantitativa de glicosaminoglicanos e ensaios enzimáticos no plasma para dosar a atividade de enzimas lisossômicas. Apesar da confirmação de mucopolissacaridose com os testes de triagem, não foi possível diferenciar entre os tipos II ou VI.

PALAVRAS-CHAVE: Cães. Doença de acúmulo lisossomal. Glicosaminoglicanas.

¹ Médica Veterinária Doutora, Professora Associada, Departamento de Clínicas Veterinárias, Universidade Estadual de Londrina (UEL), Campus Universitário, Rodovia Celso Garcia Cid, PR 445 Km 380, Londrina, PR, Brasil. CEP: 86051-990, Tel: +55433371-4559, E-mail: vicky@uel.br * [corresponding author](#)

² Médico Veterinário, Doutorando, Departamento de Medicina Veterinária Preventiva, UEL, Londrina-PR

³ Médico Geneticista, Doutor, Departamento de Medicina, PUC-PR, UNICEMP, FEPAR e diretor do Laboratório Genética, Curitiba-PR

⁴ Discente do curso de Medicina Veterinária, Departamento de Clínicas Veterinárias, Universidade Estadual de Londrina (UEL), Londrina, Paraná

⁵ Farmacêutica/Bioquímica, Doutora, Hereditare Centro de Genética Médica, Hospital de Clínicas de Porto Alegre, Rua Ramiro Barcelos, 2350, CEP: 90035-903, Porto Alegre, RS, Brasil

The mucopolysaccharidosis (MPS) disorders are lysosomal storage disorders, a group of rare inherited diseases that result from deficient activity of enzymes that degrade glycosaminoglycans (GAGs) (TURTELLI, 2002). GAGs are a component of connective tissue ground substance, and depending on the enzyme deficiency, the catabolism of dermatan, heparan, keratan, or chondroitin sulfate may be diminished singly or in combination, which results in a wide spectrum of clinical disorders that can affect central nervous system (CNS), liver, spleen, skeleton, eyes, cardiovascular and respiratory systems (WILKERSON et al., 1998; TURTELLI, 2002; SIMONARO et al., 2005).

Animal models for this syndrome include feline, canine, and caprine examples, where the disease occurs naturally (HASKINS, 2007). In humans MPS causes growth retardation, mobility problems, facial dysmorphism, hepatosplenomegaly, corneal clouding, cardiac valvular abnormalities, and mental retardation (BREIDER et al., 1989; PONDER et al., 2002). The skeletal disease of MPS is referred to as *dysostosis multiplex*, and manifests as shortened and thickened bones, bones that are abnormally shaped, and bones with articular erosion (HERATI et al., 2008).

Thirteen subclasses of mucopolysaccharidosis have been described in people (BRAUND, 2003), but in animals like dogs and cats, only MPS I, II, III A, IIIB, IV and VI are recognized (HASKINS, 2007). They have been subdivided according to enzyme defect and systemic manifestations (ASHWORTH et al., 2006). MPS I is due to deficient activity of α -L-iduronidase and results in the accumulation of heparan and dermatan sulfate. Signs include lameness, broad face with depressed nasal bridge and frontal bossing, small ears, corneal clouding, and multiple bone dysplasia (BRAUND, 2003). MPS II is due to a deficiency in iduronate-2-sulfatase, and causes coarse facial features, macrodactylia, progressive incoordination, visual impairment, corneal dystrophy, generalized osteopenia, and progressive neurologic deterioration. Mucopolysaccharidosis Type IIIA is associated with a deficiency of the lysosomal enzyme heparan sulfate sulfamidase. Around 3 years old, dogs develop progressive neurological signs of ataxia and intention tremor. Mucopolysaccharidosis Type III B is related to deficient activity of N-acetyl- α -D-glucosaminidase and clinical signs are characterized by pelvic limb ataxia, dysmetria, widebased stance, truncal swaying, occasional stumbling and falling, fine head intention tremor, and whole body tremor (BRAUND, 2003).

Mucopolysaccharidosis Type VI is caused by a deficiency of the enzyme arylsulfatase B, and clinical features of affected animals include small head, flat, broad face, wide-spaced eyes, depressed bridge of the nose, corneal clouding, small ears, large forepaws, and a concave deformity of the sternum. The MPS VII is due to deficient activity of β -glucuronidase and results in the accumulation of chondroitin, heparan, and dermatan sulfate. Clinical signs include large head, a shortened maxilla, and corneal granularities. Most joints were extremely lax and easily subluxated, with

joint capsules that were swollen and fluctuant (BRAUND, 2003).

The suspicion of MPS on the basis of clinical features will be usually followed by relatively simple tests like the histochemical staining of the cytoplasmic inclusions of circulating white cells and the demonstration of the excessive urinary excretion of GAGs (APTE, 2009). In patients with MPS, the daily excretion of GAGs is markedly increased. The Toluidine blue test is the most commonly used to detect the presence of excreted mucopolysaccharides (BRAUND, 2003; APTE, 2009). An elevated level of urinary glycosaminoglycan suggests a mucopolysaccharidosis disorder, but does not provide a specific diagnosis, so additional tests must be performed. Definitive diagnosis of MPS can only be obtained via specific enzyme deficiency testing in plasma (BRAUND, 2003, APTE, 2009). The purpose of this article is to report two cases of MPS in dogs.

A two-month-old male Pitbull was referred to be evaluated for difficulty in locomotion in four limbs and swelling in joints. He was born of an inbreeding between siblings, which gave rise two puppies. The dog in question was shorter than his brother which did not show any congenital abnormalities (Figure 1A). A physical examination showed an increasing volume of articulations, bad limb angulations with ambulation difficulties and *pectus cavinatum* (Figure 1B). In a period of 45 days, emerged mitral murmur of degree II/V, corneal opacities and inspiratory dyspnoea.

Skeletal radiographs showed *dysostosis multiplex* with abnormalities in all vertebral bodies and epiphysis of vertebral bodies with erosions (Figure 1C). Radiographs of the limbs showed several skeleton malformations, like shortened bones; focal articular erosion; degenerative joint disease; joint effusions; hip dysplasia with subluxation; elbow subluxation; curvature of long bones and *pectus cavinatum* (Figure 1 D). The complete blood count and the synovial liquid analysis were normal. The blood smear was stained with Giemsa and it was possible to identify granulations in neutrophils and monocytes. A mucopolysaccharide storage disorder was indicated by positive toluidine blue spot tests of urine.

Due to suspected MPS, a qualitative and quantitative measurement of urinary GAGs were made. Levels of dermatan sulfate and heparan sulfate were increased in urine. The strength of GAGs in urine was 405 μ g/mg creatinine (reference value = 274 μ g/mg creatinine). In plasma enzymatic assays we found 11 mol/4h/mL of iduronate-sulphatase, which is below the reference range (122-463 mol/4h/mL), activity of beta-glucuronidase equal to 574 nmol/h/mL, which is normal (reference range 30-300 nmol/h/mL) and a light deficiency of alpha-iduronidase activity (4,5 nmol/h/mL, reference = 6,8-13,7 nmol/h/mL).

Besides the symptomatic treatment with analgesics, anti-inflammatory and physiotherapy, the signs progressed and resulted in generalized muscular atrophy, occurring worsening of ambulation. When the dog completed 108-days-old, it started having seizures and was euthanized.

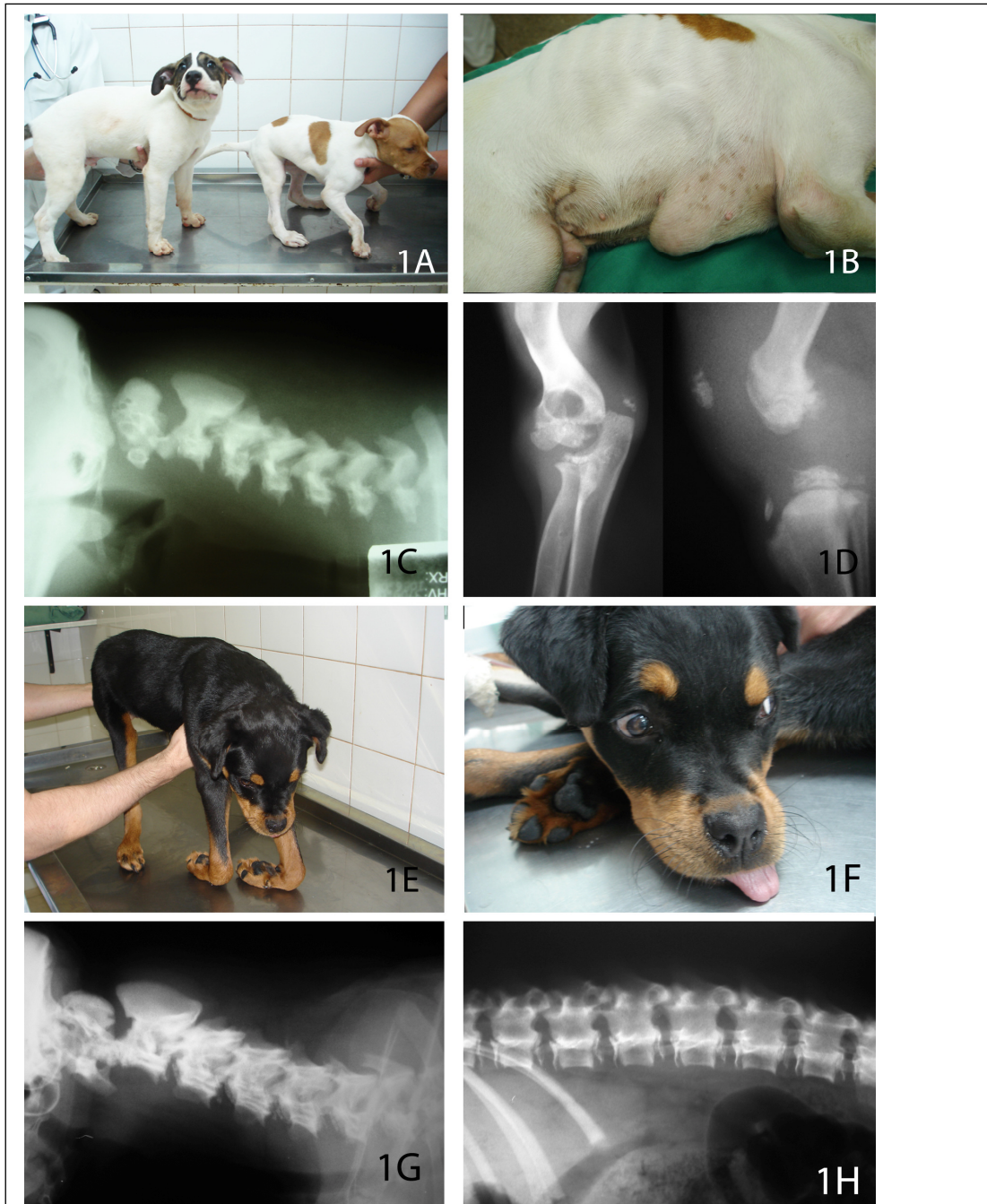


Figure 1 – **A** – Two male pit bull dogs, two-months old, that were born of an inbreeding between siblings. On the right a two-month-old male Pit bull, with bad limb angulations, shorter than his brother which did not show any congenital abnormalities (left). **B** – A two-month-old male Pit bull dog with *pectus cavinatum* due to MPS. **C** – Cervical spinal radiographs of a two-month-old male Pit bull dog, showing abnormalities in all vertebral bodies. It is possible to see that vertebral bodies are smaller than normal and there are erosion in all epiphysis of vertebral bodies. **D** – Limbs radiographs of a two-month-old male Pit bull dog. Left, elbow subluxation and focal articular erosion, and right, knee erosion and joint effusion. **E** – an eight-month-old female Rottweiler with tetraplegia. **F** – the same dog with skull deformities and enlarged tongue. **G** and **H** -- Cervical and lumbar spinal radiographs of the Rottweiler, showing abnormalities in all vertebral bodies. It is possible to see that vertebral bodies are smaller than normal and there is erosion in all epiphysis of vertebral bodies.

An eight-month-old female Rottweiler was evaluated because it was unable to walk with all members. It began presenting the problem two months before attendance, when it was hospitalized in another clinic for 20 days and soon after he was referred to our clinic. Physical examination showed tetraplegia (Figure 1E), cervical pain, skull deformities, enlarged tongue (Figure 1F), pain in all joints and corneal opacities. Skeletal radiographs showed *dysostosis multiplex*; shortened bones; focal articular erosion; joint effusions, elbow subluxation and erosion in epiphysis of vertebral bodies (Figure 1G and 1H). The complete blood count and urinalysis were normal.

A mucopolysaccharide storage disorder was indicated by positive toluidine blue spot tests of urine. Levels of dermatan sulfate and heparan sulfate were increased in urine. The strength of GAGs in urine was 281 µg/mg creatinine (reference value = 274 µg/mg creatinine). In plasma enzymatic assays we found 24 mol/4h/mL of iduronate-sulphatase, which is below the reference range (122-463 mol/4h/mL), activity of beta-galacturonidase equal to 521 nmol/h/mL, which is normal, and a light deficiency of alpha-iduronidase activity (4,5 nmol/h/MI). Due to the seriousness of the case, the clinical suspicion and the progressive nature of MPS, the dog was euthanized.

In both cases described here, mucopolysaccharidosis was diagnosed based on clinical signs and laboratory tests. However in the first case, MPS was not the prime suspect, due to the rarity of the disease in dogs, and the initial signs, especially in joints, resembled polyarthritis. Therefore, the synovial liquid analysis was done and the result was normal. With disease progression, MPS was suspected and more specific tests were performed.

The radiographical examination of both dogs showed several malformations, mainly *dysostosis multiplex*. *Dysostosis multiplex* is a hallmark of all mucopolysaccharidoses and glycoprotein storage disorders (SIMONARO et al., 2005). In case 1, the blood smear showed granulations in neutrophils and monocytes, similar to those that were seen in lysosomal storage diseases. Initial tests showed metachromatic granules in blood leukocytes, lysosomal accumulation and urinary excretion of GAGs (APTE, 2009, BRAUND, 2003). According to Ashworth et al. (2006), the initial screening test for MPS is analysis of urinary GAG excretion and the definitive test is a lysosomal enzyme assay of leucocytes, plasma cells, or fibroblasts. In these cases, a plasma assay was done to evaluate the activity of lysosomal enzymes.

In both cases, the measurement of urinary GAGs resulted in the presence of high amounts of dermatan sulfate, but the method employed does not confirm or exclude the simultaneous presence of high amounts of heparan sulfate. This measurement was suggestive of MPS type I, II, VI or VII. With the results of the plasma assays, it was possible to exclude MPS VII due to the normal activity of beta-galacturonidase and MPS I because despite the deficiency of alpha-iduronidase activity, it still remained within the normal range for dogs.

Thus, despite the confirmation of MPS with the screening tests, the type of MPS between II and VI could not be distinguished. The low activity of the enzyme iduronate-sulfatase suggests MPS type II or Hunter syndrome, but the clinical features and urinary excretion of dermatan and heparan sulfate suggests MPS VI instead (BRAUND, 2003). MPS II in dogs are not common, and has been reported only in a 5 year old male Labrador Retriever with signs of progressive incoordination, visual impairment, exercise intolerance, coarse facial features, macrodactylia, unilateral corneal dystrophy, generalized osteopenia, progressive neurologic deterioration, and a positive urine spot test for acid mucopolysaccharides (WILKERSON et al., 1998; BRAUND, 2003). MPS VI has been reported in Siamese and domestic short hair cats, as well as Miniature Pinschers, Miniature Schnauzers, Welsh Corgis, and Chesapeake Bay Retrievers, and the ensuing cellular accumulation results in skeletal deformities, including defects in the sternum and vertebrae, corneal cloudiness and facial dysmorphism (BRAUND, 2003), as seen in our patients.

The low frequency of cases, nonspecific clinical signs and very limited knowledge among medical professionals contributed to the difficult recognition of the disease, so MPS should have also been included in the differential diagnosis for growth abnormalities in puppies. In conclusion, the clinician should be alert and consider MPS in dogs that have skeletal malformations, because it is important to be aware of the possible risk the reproduction of these animals or their parents, since all types of MPS are genetically inherited. Animal with MPS have significant clinical signs and lesions in the same organ systems as human patients, including the central nervous system, skeleton, eye and cardiovascular system and could be of great importance in the development of therapy for this disease in humans (HASKINS, 2007).

REFERENCES

- APTE B. N. A. Simple and rapid method for the diagnosis of mucopolysaccharidoses (Mps). **Journal of Clinical and Diagnostic Research**. v.3, p.1488-1492, 2009.
- ASHWORTH, J. L.; BISWAS, S.; WRAITH, E.; LLOYD, I. C. Mucopolysaccharidoses and the eye. **Survey of Ophthalmology**, v.51, n.1, p.1-17, 2006. Available from: <[http://ophsource.org/periodicals/sop/article/S0039-6257\(05\)00198-0/abstract](http://ophsource.org/periodicals/sop/article/S0039-6257(05)00198-0/abstract)>. Accessed: 24 sep. 2010. doi: 10.1016/j.survophthal.2005.11.007.
- BRAUND, K. G. Storage disorders. In: **Clinical neurology in small animals: localization, diagnosis and treatment**. 2003. New York: International Veterinary Information Service. Available from: <www.ivis.org/advances/vite/braund18/ivis.pdf>. Accessed 24 sep.2010.

BREIDER, M. A.; SHULL, R. M.; CONSTANTOPOULOS, G. Long-Term effects of bone marrow transplantation in dogs with mucopolysaccharidosis I. **The American Journal of Pathology**, v.134, n.3, p.677-692, 1989.

HASKINS, M. E. Animal models for mucopolysaccharidosis disorders and their clinical relevance. **Acta Paediatrica**, v.96, p.56-62, 2007.

HERATI, S. E.; KNOX VAN W.; O'DONNELL, P.; D'ANGELO, M.; HASKINS, M. E.; PONDER, K. P. Radiographic evaluation of bones and joints in mucopolysaccharidosis I and VII dogs after neonatal gene therapy. **Molecular Genetics and Metabolism**, v.95, p.142-151, 2008.

KAKKIS, E. D.; SCHUCHMAN, E.; HE, S.; WAN, Q.; KANIA, S.; WIEMELT, S.; HASSON, C. W.; O'MALLEY, T.; WEIL, M. A.; AQUIRREGA, BROWN, D. E., HASKINS, M. E. Enzyme replacement therapy in feline mucopolysaccharidosis I. **Molecular Genetics and Metabolism**, v.72, n.3, p.199-208, 2001. Available from: <<http://www.ncbi.nlm.nih.gov/pubmed/11243725>>. Accessed: 24 sep. 2010. doi: 10.1006/mgme.2000.3140

PONDER, K. P.; JOHN, R.; MELNICZEK, J. R.; XU, L.; WEIL, M. A.; O'MALLEY, T. M.; O'DONNELL, P. A.; KNOX, W. W.; AGUIRRE, G. D.; MAZRIER, H.; ELLINWOOD, N. M.; SLEEPER, M.; MAGUIRE, A. M.; VOLK, S. W.; MANGO, R. L.; ZWEIGLE, J.; WOLFE, J.; HASKINS, M. E. Therapeutic neonatal hepatic gene therapy in mucopolysaccharidosis VII dogs. **Proceedings of the National Academy of Sciences of the United States of America**, v.99, n.20, 2002. Available from: <<http://www.pnas.org/content/99/20/13102.full>>. Accessed: 21 sep. 2010. doi: 10.1073/pnas.192353499

SIMONARO, C. M.; D'ANGELO, M.; HASKINS, M.E.; SCHUCHMAN, E. H. Joint and bone disease in mucopolysaccharidoses VI and VII: identification of new therapeutic targets and biomarkers using animal models. **Pediatric Research**, v.57, n.5, p.701-707, 2005.

TURTELLI, C. M. Manifestações radiológicas da mucopolissacaridose tipo IV. **Radiologia Brasileira**, São Paulo, v.35, n.5, p.311-314, 2002.

WILKERSON, M. J.; LEWIS, D. C.; MARKS, S. L.; PRIEUR, D. J.. Clinical and morphologic features of mucopolysaccharidosis type II in a dog: naturally occurring model of Hunter syndrome. **Veterinary Pathology**, v.35, n.3, p.230-233, 1998. Available from: <<http://vet.sagepub.com/content/35/3/230.abstract>>. Accessed: 24 sep. 2010. doi: 10.1177/030098589803500311