

RADIOGRAPHIC FINDINGS OF UREMIC PNEUMONITIS IN DOGS WITH CHRONIC RENAL FAILURE

ACHADOS RADIOGRÁFICOS DE PNEUMONITE URÊMICA EM CÃES COM INSUFICIÊNCIA RENAL CRÔNICA

**D. PAULINO JR^{1*}; M. C. TONI²; A. E. W. B. MEIRELLES²; J. C. CANOLA²;
A. A. CAMACHO²**

SUMMARY

Kidney disease can progress relentlessly and takes the patient to a state of chronic renal failure (CRF) and, subsequently, to renal failure. Several systemic changes arising from the CRF are cited in the literature, and one of the most important is high level of seric urea, which can lead to pneumonitis. In order to identify the pulmonary alterations caused by CRF, radiographs were performed in 30 adult male and female dogs. The animals were divided into two groups (GI and GII). The control group (GI) consisted of 10 healthy dogs while GII of 20 dogs with CRF. The animals were patients of the Veterinary Hospital "Governador Laudo Natel" and were selected after screening their anamnesis, clinical and laboratorial exams. Dogs of GI and GII had the thoracic region imaged in right lateral and ventrodorsal projections for evaluation of heart size and pulmonary patterns. The heart size was assessed by vertebral heart score (VHS) and subjectively. The values found for VHS were 10.55 ± 0.68 vertebral bodies for GI and 10.30 ± 0.52 vertebral bodies for GII. The qualitative assessment showed cardiac right and left enlargement in most of the GII animals, unlike the GI with right side enlargement only. No difference was noted ($p = 0.2757$) for VHS between the two groups of animals, but 100% of the dogs of GII exhibited pulmonary pattern compatible with pneumonitis.

KEY-WORDS: Canine. Pneumonitis. Uremia.

RESUMO

A doença renal pode progredir de forma implacável e leva o paciente ao estado de insuficiência renal crônica (IRC) e, na sequência, à falência renal. Várias alterações sistêmicas decorrente da IRC são citadas na literatura, e entre uma das mais importantes os altos níveis séricos de uréia, caracterizando a pneumonite. Com o objetivo de identificar as alterações pulmonares, através de exames radiográficos de cães com insuficiência renal crônica (IRC), realizou-se este estudo com 30 cães adultos, dentre machos e fêmeas. Os animais foram distribuídos em dois grupos. O grupo controle (GI) foi constituído por 10 cães hígidos e GII por 20 cães com IRC. Os animais, provenientes da rotina do Hospital Veterinário "Governador Laudo Natel", foram classificados após triagem composta por anamnese, exame clínico e laboratorial. Os cães do GI e GII tiveram a região torácica radiografada, em projeções lateral direita e ventrodorsal, para avaliação das dimensões cardíaca e padrões pulmonares. O tamanho cardíaco foi avaliado por meio de escore cardíaco vertebral (VHS) e de maneira subjetiva. Os valores encontrados pelo método VHS foram de $10,55$ corpos vertebrais $\pm 0,68$ para o GI e $10,30$ corpos vertebrais $\pm 0,52$ para o GII. Na avaliação qualitativa encontrou-se aumento de área cardíaca direita e esquerda em grande parte dos animais do GII, diferentemente do GI onde somente foi observado aumento de área cardíaca direita. Não foi constatada diferença ($p = 0,2757$) em relação à área cardíaca pelo método VHS entre os dois grupos de animais, todavia 100% dos cães do GII apresentaram padrão pulmonar representativo de pneumonite.

PALAVRAS-CHAVE: Canino. Pneumonite. Uremia.

¹ Universidade de Franca – UNIFRAN. * Autor para correspondência: danielcardio@yahoo.com.br

² Universidade Estadual Paulista (UNESP), Jaboticabal, SP, Brasil.

INTRODUCTION

Chronic kidney disease (CKD) leads to chronic renal failure (CRF) and, subsequently, to kidney failure, which may result in death. The kidneys are essential to homeostasis, and play a fundamental role in the regulation of systemic blood pressure (SBP), and endocrine functions (YU et al., 2002).

CKD is often progressive and independent of the initial injury, which can result from various causes, and subsequently compromise the glomeruli, tubules and interstitium, culminating with the loss of nephrons and decreasing glomerular filtration rate (GFR) (Brown et al., 2007).

Kidney impairment is characterized by decreased ability to concentrate urine and difficulty in maintaining homeostasis of water and electrolytes. With the progression of lesions in the structural and/or functional mass of one or both kidneys, nephron loss occurs and the patient presents uremia, characterized by azotemia, polyuria, polydipsia, anorexia, among others (SHIMIZU, 2005; WAKI et al. 2010).

When 70% to 75% of the nephrons are compromised, non-protein nitrogenous compounds start to accumulate in the blood due to decreased GFR and if systemic consequences of CKD are extensive, uremia may be present in varying degrees (POLZIN & OSBORNE, 1997).

Uremia is defined as abnormal presence of urea and other nitrogenous compounds in the blood. The clinical signs secondary to uremia, such as sodium and water imbalance, metabolic acidosis, pneumonitis and anemia may be classified as uremic syndrome (NELSON, 2001).

Among the known CRF symptoms, pneumonitis has been little emphasized, especially in imaging diagnostics. The term uremic pneumonitis was first used in 1954 to describe pathologic changes in the lungs of patients with uremia (HOPPS, 1955).

Usually followed by vasculitis, pneumonitis is not present with pulmonary consolidation, but with increased radiopacity due to interstitial inflammation of the bronchi terminals (NELSON, 2001; LORIGADOS, 2005).

The objective of this work is to assess pulmonary changes compatible with pneumonitis in thoracic radiographs of dogs with duly proven CRF.

MATERIAL AND METHODS

We used 30 adult dogs, males and females of several races, weighing on average 16 kg, average age 10 years, divided into two groups. Group GI (control) consisted of 10 healthy dogs from the kennel of the Laboratory of Nutrition and Nutritional Diseases of the Faculdade de Ciências Agrárias e Veterinárias (FCAV) da Unesp, Jaboticabal, SP. Group II consisted of 20 adult dogs with acquired chronic renal failure (CRF) that were seen at the Veterinary Hospital of the institution.

Anamneses, physical examination, complete blood count, urinalysis and serum biochemical profile, were performed to screen the animals to participate in the study. Blood and urine samples were collected from all animals for complete blood count, renal serum biochemical profile (urea and creatinine), urinalysis and to calculate the ratio urinary protein/ creatinine (U-P/C). In addition, chest radiographs were performed in right lateral and ventral dorsal projections at the Imaging Diagnosis Sector for evaluation of pulmonary and cardiac dimensions. The heart size was measured by a double-blind study using the heart score objective method, VHS (Vertebral Heart Scale), proposed by BUCHANAN & BÜCHELER (1995) and the average measurement determined. The subjective evaluation was performed by analysis of both radiographic projections.

Statistical analysis was performed using the unpaired *t* test to compare means between groups.

The animals of GII were classified as CRF when polyuria and polydipsia of renal origin were concomitant while serum creatinine was greater than 1.50 mg/dL, urea greater than 74.0 mg/dL (azotemia), and urinalysis showed density less than 1.020.

This study was conducted in accordance with the ethical principles of animal experimentation adopted by the Brazilian College of Trial (Colégio Brasileiro de Experimentação, COBEA) and approved by the Ethics and Animal Welfare (Comissão de Ética e Bem Estar Animal, CEBEA), of the Faculdade de Ciências Agrárias e Veterinárias (FCAV), UNESP, Jaboticabal under protocol number 011 590.

RESULTS AND DISCUSSION

The average heart measurement by the VHS method was 10.55 ± 0.68 vertebral bodies (VB) for GI and 10.30 ± 0.52 VB for GII. BUCHANAN & BÜCHELER (1995) established as normal value an average of 9.7 ± 0.5 vertebral bodies. Therefore, both groups in this study had a mildly enlarged cardiac area. No significant difference ($p = 0.2757$) was found between the groups for VHS. This method is widely used by radiologists in routine cardiac evaluation and several studies confirm its efficacy when related to subjective assessment, electrocardiographic and echocardiographic (LAMB et al., 2000; SLEEPER & BUCHANAN, 2001; NAKAYAMA et al., 2001). Some studies reveal that there are racial differences and some breeds such as Yorkshire Terrier and Beagle are predominantly affected by diseases with distinct characteristics (e.g., cardiac dilation versus concentric hypertrophy) (LAMB et al.2000; KRAETSCHMER et al., 2007; CASTRO et al., 2011). According to the subjective analysis, the right side of the heart was enlarged in 100% of the animals of both groups, GI and GII while some dogs from GII showed enlargement of the left side, as well. The cardiac enlargement determined by the subjective evaluation was relatively discreet, which may explain the normal values found in the objective assessment (VHS), noting

that merely numerical ratings can generate false positive diagnosis. Enlargement of the right side of the heart may be explained by aging and chronic obstructive pulmonary disease, as well as the very pneumonitis that was seen in radiographs caused by uremia in this case. This enlargement can be attributed to increased workload on the right side of the heart to pump blood to an area of pulmonary resistance (LAMB, 2007). It is believed that, for the dogs of GII, the enlarged right side of the heart was due to pneumonia since there was no radiographic evidence of either pulmonary obstructive disorders or senility. On the other hand, in some dogs of GI, this enlargement may be related to pulmonary pattern compatible with senility.

The enlarged left side of the heart, observed in various dogs of GII can be explained by systemic hypertension due to CRF (BROWN et al. 2007; CASTRO, 2007), attributed especially to

glomerulonephritis because the increased pressure causes the left side of the heart to beat as to overcome the vascular resistance, thus inducing myocardial hypertrophy (CASTRO, 2007).

There are contradictions regarding the term pneumonitis. Some authors use it as a synonym for pneumonia while others prefer terms such as pneumonia uremic syndrome (FAUBEL, 2008) or interstitial pneumonitis (DROST, 1997; GONÇALVES, et al., 2003). The term pneumonitis was used in this work to qualify on radiographic images increased diffuse radiopacity of the pulmonary interstitium, classified as interstitial pattern, associated with thickening bronchioles and vasculitis. This type of lesion, found in 100% of group II dogs, was different from the interstitial and bronchial patterns related to senility observed in dogs over 10 years of GI (Figure 1).

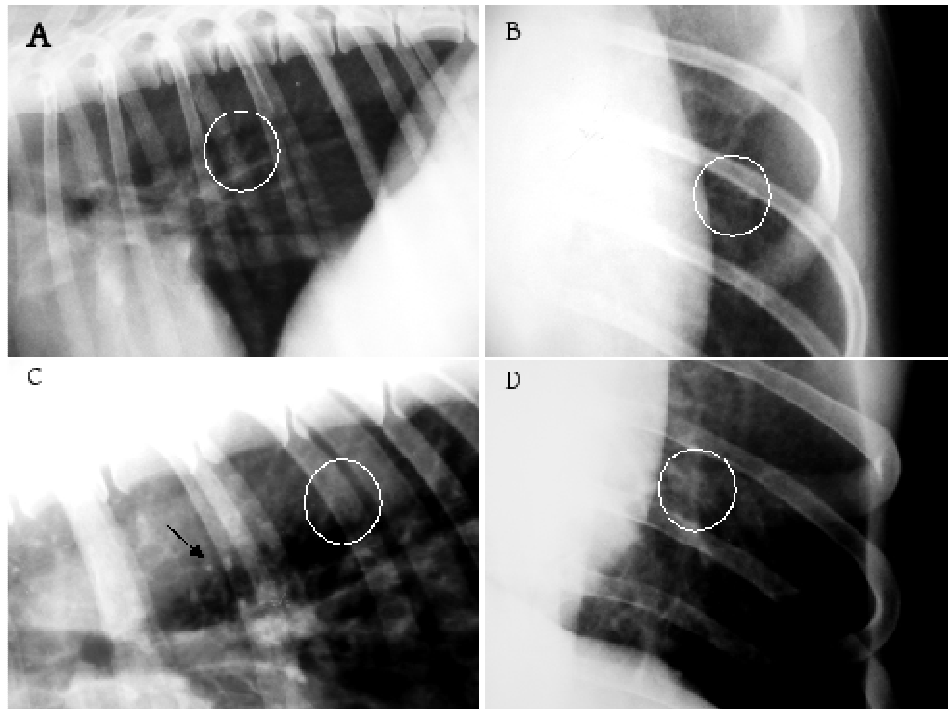


Figure 1 - Radiographic image showing in detail the lung in the right lateral projection (A) and ventrodorsal (B) of a healthy dog with increased opacity of bronchi compatible with senility (white circle), right lateral (C) and ventrodorsal (D) projection of a dog with chronic renal failure (CRF) presenting vasculitis (black arrow), and diffuse interstitial pulmonary pattern showing thickening bronchioles compatible with uremic pneumonitis (white circle).

The Injury of pneumonitis found in this work was related to uremia due to CRF, but the radiographic image of this pulmonary pattern can occur in systemic lung diseases such as rickettsia (DROST, 1997), distemper and leishmaniasis (GONÇALVES et al., 2003; LAMB, 2007). Regarding laboratory parameters, UPC values found were 0.2010 ± 0.1905 (GI) and 2.1810 ± 0.782 (GII) with significant increase of the

UPC of GII dogs compared to GI ($p < 0.0001$). Urine specific gravity was 1.024 ± 0.0034 (GI) and 1.011 ± 0.0034 (GII), with decreased urine specific gravity with the same correlation.

Low urinary density and renal azotemia are laboratory findings in animals with CRF that lose the ability to concentrate urine (ZATZ, 2000) and with increased non-protein nitrogen compounds in the blood

as a result of decreased glomerular filtration rate (POLZIN & OSBORNE, 1997).

The GII dogs had azotemia, unlike GI dogs. Furthermore, 85% of GII dogs with suspected glomerulonephritis, showed intense proteinuria as demonstrated by the UPC variable, as cited by GRAUER (2009).

CONCLUSION

The vascular and diffuse interstitial pulmonary pattern characterized as pneumonitis found in 100% of animals with chronic renal failure was explained by uremia. The same radiographic image can also occur when some infectious diseases, such as distemper among others, are present; therefore, an accurate clinical examination of the patient is imperative.

REFERENCES

- BUCHANAN, J. W.; BÜCHELER, J. Vertebral scale system to measure canine heart size in radiographs. **Journal of the American Veterinary Medical Association**, v.206, p.194-199, 1995.
- BROWN, S.; ATKINS, C.; BAGLEY, R.; CARR, S.; COWGILL, L.; DAVIDSON, M.; EGNER, B.; ELLIOT, J.; HENIK, R.; LABATO, M.; LITTMAN, M.; POLZIN, D.; ROSS, L.; SNYDER, P.; STEPIEN, R. Guidelines for the identification, evaluation, and management of systemic hypertension in dogs and cats. **Journal of Veterinary Internal Medicine**, v.21, p.542-558, 2007.
- CASTRO, C. A. J. Hipertensão arterial en pequeños animales. In: BELERENIAN, G. C.; MUCHA, C. J.; CAMACHO, A. A.; GRAU, J. M. **Afecciones cardiovasculares en pequeños animales**. 2ªed., p.379-398, Buenos Aires: Inter-médica, 2007.
- CASTRO, M. G.; TÔRES, R. C. S.; ARAÚJO, R. B.; MUZZI, R. A. L.; SILVA, E. F. Avaliação radiográfica da silhueta cardíaca pelo método *vertebral heart size* em cães da raça Yorkshire Terrier clinicamente normais. **Arquivos Brasileiros de Medicina Veterinária e Zootecnia**, v.63, p.850-857, 2011. Disponível em: <http://www.scielo.br/pdf/abmvz/v63n4/09.pdf>.
- DROST, T.; BERRY, C. R.; BREITSCHWERDT, E. B.; DAVIDSON, M. Thoracic radiographic findings in dogs infected with *RICKETTSIA RICKETTSII*. **Veterinary Radiology & Ultrasound**, v.38, p.260-266, 1997. Disponível em: <http://www3.interscience.wiley.com/journal/11916213/2/abstract>. Doi: 10.1111/j.1740-8261.1997.tb00852.x
- FAUBEL, S. Pulmonary complications after acute kidney injury. **Advances in Chronic Kidney Disease**, v.15, p.284-296, 2008. Disponível em: Doi: [10.1053/j.ackd.2008.04.008](http://dx.doi.org/10.1053/j.ackd.2008.04.008)
- GRAUER G. F. [2009]. Diagnosis, management of hypertension, proteinuria in dogs with chronic renal disease. **DVM Newsmagazine**. Disponível em: <http://veterinarynews.dvm360.com/dvm/Medicine/Diagnosis-managementofhypertesionroteiruiai/ArticleStandard/Article/detail/591639?contextCategoryId=45705>>. Acesso em 09 de abril de 2012.
- GONÇALVES, R.; TAFURI, W. L.; MELO, M. N.; RASO, P.; TAFURI, W. L. Chronic interstitial pneumonitis in dogs naturally infected with *Leishmania (Leishmania) chagasi*: a histopathological and morphological study. **Revista do Instituto de Medicina Tropical de São Paulo**, v.45, p.153-158, 2003. Disponível em: http://www.scielo.br/scielo.php?script=sci_arttext&pid=S0036-46652003000300007&lng=pt&nrm=iso. Doi: 10.1590/S0036-46652003000300007.
- HOPPS, H. C.; WISSLER, R. W. Uremic pneumonitis. **American Journal of Pathologist and Bacteriologists**. p.261-273, 1955.
- KRAETSCHMER, S.; MENESES, L. F.; NOLTE, I.; SIMON, D. Vertebral heart scale in the beagle dog. **Journal of Small Animal Practice**, v.49, p.240-243, 2007. Disponível em: <http://www3.interscience.wiley.com/journal/11939403/5/abstract> Doi: 10.1111/j.1748-5827.2007.00531.x
- LAMB, C. R. The canine and feline lung. In: THRALL, D. E. **Textbook of veterinary diagnostic radiology**. 5ª ed. p. 591-608, Missouri: Saunders Elsevier, 2007.
- LAMB, C. R.; TYLER, M.; BOSWOOD, A.; SKELLY, B. J.; CAIN, M. Assessment of the value of the vertebral heart scale in the radiographic diagnosis of cardiac disease in dogs. **The Veterinary Record**, v.146, p. 687-690, 2000.
- LORIGADOS, C. A. B. Pneumonia. In: FARROW, C. S. **Veterinária - Diagnóstico por imagem do cão e gato**. 1ª ed. p.409-420, São Paulo: Roca, 2005.
- NAKAYAMA, H.; NAKAYAMA, T.; HAMLINXIA, R. L. Correlation of Cardiac Enlargement as Assessed by Vertebral Heart Size and Echocardiographic and Electrocardiographic Findings in Dogs with Evolving Cardiomegaly Due to Rapid Ventricular Pacing. **Journal of Veterinary Internal Medicine**, v.15, p.217-221, 2001. Disponível em: <http://www3.interscience.wiley.com/journal/11982563/4/abstract> Doi: 10.1111/j.1939-1676.2001.tb02314.x
- NELSON, R. W.; COUTO, C. G. Distúrbios do parênquima pulmonar. In: **Medicina interna de pequenos animais**. 2ª ed. p.235-246, Rio de Janeiro: Guanabara Koogan, 2001.

POLZIN, D. J.; OSBORNE, C. A.; BARTGES, J. W.; JAMES, K. M.; CHURCHILL, J. A. Insuficiência renal crônica. In: ETTINGER, S. J.; FELDMAN, E. C. **Tratado de medicina interna veterinária**, 4ªed. p.2394-2431, São Paulo: Manole, 1997.

SLEEPER, M. M.; BUCHANAN, J. M. Vertebral scale system to measure heart size in growing puppies. **Journal of the American Veterinary Medical Association**, v.219, p.57-59, 2001. Disponível em: <http://avmajournals.avma.org/doi/abs/10.2460/javma.2001.219.57>. doi: 10.2460/javma.2001.219.57.

SHIMIZU, M. H. M.; COIMBRA, T. M.; ARAUJO, M.; MENESES, L. F.; SEGURO, A. C. N-acetylcysteine attenuates the progression of chronic renal failure. **Kidney International**, v. 68, p.2208-2217, 2005. Disponível em: <http://www.nature.com/ki/journal/v68/n5/abs/4496365a.html> Doi: 10.1111/j.1523-1755.2005.00677.x

YU, L.; BURDMANN, E.; SEGURO, A. C.; HELOU, C. M. B. Insuficiência renal aguda. In: ZATZ, R. **Fisiopatologia renal**. p.261-282, São Paulo: Atheneu, 2002.

WAKI, M. F.; MARTORELLI, C. R.; MOSKO, P. E.; KOGIKA, M. M. Classificação em estágios da doença renal crônica em cães e gatos – abordagem clínica, laboratorial e terapêutica. *Ciência Rural*, v.40, n.10, p.2226-2234, 2010. Disponível em: <http://www.scielo.br/pdf/cr/2010nahead/a741cr3532.pdf>

ZATZ, R. Insuficiência renal crônica. In: **Fisiopatologia Renal**. p. 283-300. São Paulo: Atheneu, 2002.