

UTERINE TORSION IN DOMESTIC FELINE - CASE REPORT

TORÇÃO UTERINA EM FELINO DOMÉSTICO – RELATO DE CASO

Í. S. DAL-BÓ^{1*}, T. O. CORRÊA², M. P. FERREIRA¹, F. S. NÓBREGA¹,
R. IDALENCIO², M. V. BRUN³

SUMMARY

Uterine torsion is defined as a rotation of more than 45° around the longitudinal axis of one or both uterine horns more commonly observed in multiparous females. Nonspecific clinical signs generally reflect abdominal pain. Diagnosis is confirmed by exploratory celiotomy. Surgical treatment is urgent and should be performed as soon as possible. This assay reports the uterine torsion diagnosed in an 11-year-old mixed breed cat. The patient was referred with severe lethargy, hypothermia, abdominal pain and bloody vaginal discharge. Its mucous membranes were pale and dry, the extremities were cold, estimated dehydration was 10% and peripheral pulse was not palpable. The patient also had bloating and abdominal tenderness. The ultrasound exam revealed the presence of fetuses without heartbeat and a small amount of free liquid in the abdominal cavity. The patient was referred for ovariohysterectomy surgery after emergency treatment. The resection in bloc technique was performed removing both ovaries and uterus. Despite the intensive care, the animal did not recover and died hours later.

KEY WORDS: Acute abdomen. Pregnancy. Ovariohysterectomy. Septic shock.

RESUMO

A torção uterina é definida como a rotação de um ou dois cornos uterinos, ou ainda de todo o útero, sobre seu eixo longitudinal, sendo mais frequente em fêmeas múltíparas. Os sinais clínicos são inespecíficos e, em geral, refletem dor abdominal, sendo o diagnóstico definitivo mais frequentemente realizado por meio de celiotomia exploratória. O tratamento dessa afecção é cirúrgico, devendo ser realizado o mais breve possível. O presente relato descreve um caso de torção uterina em um felino doméstico, sem raça definida e 11 anos de idade, que apresentava intensa letargia, hipotermia, extremidades frias, mucosas pálidas e secas, desidratação estimada em 10%, distensão abdominal e algia à palpação, pulso periférico não palpável e secreção vaginal de coloração sanguinolenta. Na ultrassonografia abdominal foi observada presença de fetos, ausência de batimentos cardíacos fetais e pequena quantidade de líquido livre na cavidade. Após estabilização do quadro clínico, a paciente foi encaminhada para cirurgia de ovariosalpingohisterectomia. O procedimento foi realizado sem desfazer a torção uterina, com o útero e ovários sendo removidos em bloco. O animal ficou sob cuidados intensivos, porém foi a óbito quatro horas após a intervenção cirúrgica.

PALAVRAS-CHAVE: Abdômen agudo. Endotoxemia. Gestação. Ovariosalpingohisterectomia.

^{1*} Faculdade de Medicina Veterinária e Zootecnia da Universidade de São Paulo (FMVZ-USP), Av. Prof. Dr. Orlando Marques de Paiva, 87. ZIP 05508-270. São Paulo, SP, Brazil. Corresponding author: idb_vet@yahoo.com.br

² Hospital Veterinário da Universidade de Passo Fundo (HV-UPF), Passo Fundo, RS, Brasil.

³ Departamento de Clínica de Pequenos Animais, Centro de Ciências Rurais (CCR), Universidade Federal de Santa Maria (UFSM), Santa Maria, RS, Brasil.

INTRODUCTION

Uterine torsion is uncommon in small animals, but it is more frequently described in cats (SILVA, 2008) and, therefore, should be considered as a differential diagnosis when vaginal secretion and acute abdomen are observed (LA PUERTA et al., 2008; CHAMBERS et al., 2011). Uterine torsion is defined as rotation of one or two uterine horns, or the entire uterus about its longitudinal axis; and is more commonly observed in multiparous females (THILAGAR et al., 2011). Its etiology is unknown, but may be associated with the broad ligament laxity of the uterus; fetal movements; uterine contractions; presence of flaccid uterine walls or long/sagging mesometrium, or even the small amount of fetal fluids; obstetric maneuvers during dystocia and excessive physical activity during pregnancy (STONE, 2007). Clinical signs are nonspecific and, generally, reflect abdominal pain while anorexia, lethargy, bloating or abdominal tension and vaginal discharge can also be observed (STANLEY & PACCHIANA, 2008).

After the torsion, uterine irrigation and drainage are compromised, leading to necrosis of uterine tissue and placental abruption, as well as metabolic and hematological disorders (RIDYARD et al., 2000), which may progress to peritonitis, endotoxemia and disseminated intravascular coagulation (DE LA PUERTA et al., 2008). The clinical signs and hemodynamic changes of this condition are directly proportional to the torsion degree, which can vary between 180 and 900° both clockwise and counter-clockwise, this parameter being considered as an indicator of prognosis (THILAGAR et al., 2011).

The treatment is surgical, should be performed as soon as possible and includes the administration of fluid therapy and antibiotics. If the fetuses are viable, a cesarean section is performed before ovariosalpingohysterectomy (OSH) (SILVA, 2008). The OSH must be performed without repositioning the uterus while minimizing the release of inflammatory mediators and endotoxin into blood circulation (LA PUERTA et al., 2008). The prognosis, according to Ridyard et al. (2000) and Silva (2008), is good when initial support treatment and early surgical intervention are performed.

The present report describes a case of uterine torsion in a domestic feline.

CASE REPORT

An 11 year-old, non-defined breed female cat, weighing 5 kg, was seen at the Veterinary Hospital of the Universidade de Passo Fundo (UPF-HV) due to intense lethargy and abdominal discomfort after remaining approximately 72 hours without contact with the owners. No information was available on estrus and the possibility of pregnancy. Physical examination showed intense lethargy, hypothermia (32.3°C), cold extremities, pale and dry mucous membranes, capillary refill time of three seconds, 10% estimated

dehydration, peripheral pulse not palpable, abdominal distention and localized pain on palpation, heart rate of 120 beats per minute and bloody vaginal discharge.

An oxygen mask was placed immediately and the animal was warmed up with blanket and hot water bottles. The intravenously (IV) fluid therapy used 60 mL/kg of the crystalloid, sodium lactate ringer (SLR), associated with 10 ml/kg oxypolygelatin. Intravenously dopamine therapy was also instituted at a dose of 5 µg/kg/min diluted in NaCl 0.9% in order to normalize blood pressure. The painkiller tramadol hydrochloride (4 mg/kg) was given subcutaneously (SC), while cephalothin (30 mg/kg) associated with metronidazole (30 mg/kg) were injected intravenously as antibiotics. Furosemide (2 mg/kg, IV) was also administered in the fluid therapy.

Complete blood count (CBC) revealed severe normocytic and normochromic anemia; erythrocyte count of $1.96 \times 10^9/\mu\text{L}$, hemoglobin of 3.0 g/dL, hematocrit 9%, leukocyte count of $15.7 \times 10^3/\mu\text{L}$ and platelets $260 \times 10^3/\mu\text{L}$, and the presence of toxic neutrophils (+), anisocytosis (+), Howell-Jolly corpuscle/bodies and erythrocyte ghosts. Serum albumin, ALT, creatinine and ALP were within the reference values for the species; however, serum urea was 118 mg/dL. Urethral catheterization was performed to collect urine sample and kept in a closed system to monitor urinary output. Urinalysis showed the following changes: high density (1099), slightly cloudy appearance, proteinuria (+ + +), presence of squamous (1 to 2 per field), transitional (0 to 1/field) and caudata (rare) cells; as well as the presence of mucus (+), bacteria (+), struvite crystals (+) and fat droplets (+ +). The initial urine output was 0.5 ml/kg/h.

Based on the results of the CBC, a whole blood transfusion was performed. After clinical stabilization, the patient was referred for abdominal ultrasound, which indicated the presence of fetuses, absence of fetal heartbeat and small amount of free fluid in the cavity. Subsequently, the animal underwent exploratory laparotomy. The anesthetic protocol was pre-oxygenation with mask, followed by induction with propofol (1 mg/kg, IV), tracheal intubation and maintenance of anesthesia with isoflurane vaporized in 100% oxygen in semi-open system.

A standard midline retroumbilical laparotomy was performed; and a free dark bloody fluid was observed in the abdominal cavity while the uterus was dark-colored and friable. Furthermore, fetuses were present only in the left uterine horn and a clockwise torsion of approximately 540° could be seen (Figure 1 - A, B and C). Ovariohysterectomy was performed without undoing the uterine torsion, removing the uterus and ovaries in block. The ovarian pedicle and uterine body were sutured using 3-0 monofilament nylon. The abdominal cavity was washed with warm 0.9% NaCl solution and sutured with 2-0 monofilament nylon in simple continuous pattern. The synthesis of the subcutaneous tissue followed the same pattern using 3-0 monofilament nylon and dermal suture with 4-0 monofilament nylon, also using the simple continuous pattern.

Upon macroscopic examination, it was observed that the uterus had separated into two compartments due to rotation. Five fetuses were inside the uterus, of which four were in the cranial compartment (twisted), and one in the caudal compartment (Figure 1 - D, E and F). Fetal age was estimated at 35 days based on the developmental stage of the fetus in the caudal compartment. However, the four fetuses found in the cranial compartment had delayed development compared to the first, and hemorrhagic appearance, as well. There were no fetuses in the right horn, but it was filled up with bloody content.

The patient remained hospitalized in intensive care receiving fluid with RLS, cephalothin, metronidazole, tramadol hydrochloride and furosemide, at the initial doses. However, the cat died four hours after surgery.

DISCUSSION

The uterine torsion is an uncommon condition in cats and may be associated with the final third period of gestation (THILAGAR et al., 2011). The clinical presentation occurs with clinical signs of acute abdomen (DE LA PUERTA et al., 2008), as was observed in this case, where the animal came to the veterinary hospital presenting abdominal distension and pain. This condition can lead to peritonitis, sepsis, endotoxemia, and disseminated intravascular

coagulation, especially when the torsion is due to fetal death or pyometra (DE LA PUERTA et al., 2008).

The favorable prognosis is related to support treatment to stabilize the clinical condition as early as possible (RIDYARD et al., 2000). Following this recommendation, at the time the animal was admitted to hospital, the procedures for reversing the signs of shock, determining the diagnosis and referring for surgical procedure were started immediately.

The haematological tests showed severe normocytic and normochromic anemia compatible with blood loss, which may be related to the large volume of blood in the uterus and vascular stasis of uterine vessels due to torsion (RIDYARD et al., 2000; THILAGAR et al., 2011). Furthermore, the blood loss due to the shock syndrome was already established preoperatively. When the hematocrit and hemoglobin values are low, as in our case, whole blood therapy is essential, and this should be performed when hematocrit values are below 20% and hemoglobin values below 7 mg/dL (GOMES, 2008). The alterations found in urinalysis such as high density, proteinuria and the presence of caudata cells associated to dehydration, severe anemia and low urine output, were indicative of acute renal failure, despite the fact that serum creatinine value was normal for the species. As recommended by Merlo (2008), renal lesion was treated with intensive fluid administration and urine output was normalized.

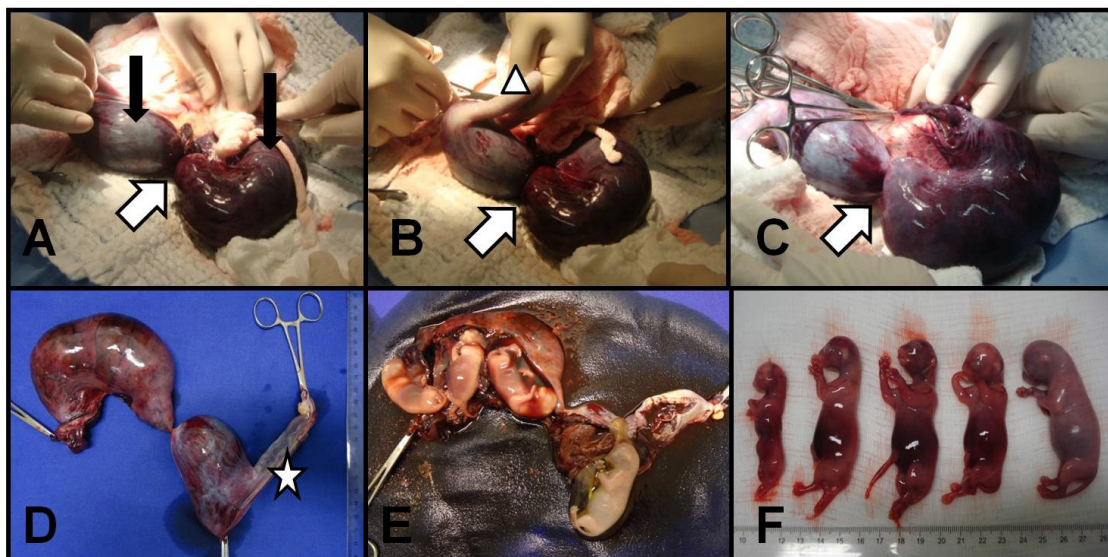


Figure 1. A, B and C - Intraoperative images of the uterine torsion and postoperative photos of the womb and fetus. Left uterine horn (black arrows), torsion point of the left uterine horn (white arrow) and right uterine horn (white triangle). D - Macroscopic appearance of the uterus after OH. Left uterine horn divided into two compartments. White Star: right uterine horn. E - Hysterectomy and identification of four fetuses in the cranial compartment and one fetus in the caudal compartment. F - fetuses at different stages of development.

The abdominal ultrasound was essential for the diagnosis of fetal death and the presence of free fluid, however, the definitive diagnosis of uterine torsion was reached only with exploratory laparotomy. As the torsion of the left uterine horn was identified, OH was performed without repositioning of the uterus to minimize the release of endotoxin and inflammatory mediators into the bloodstream, as recommended by Stanley & Pacchiana (2008).

During uterine torsion, the occlusion of blood vessel occurs, with subsequent engorgement and rupture leading to intraluminal bleeding and tissue ischemia (RIDYARD et al., 2000). In ischemic environment, oxygen free radicals are formed, which activate lipid peroxidation and alter the function and structure of cell membranes, increasing vascular permeability (MOSTAJERAN et al., 2007). The edema present in the Ischemia-reperfusion syndrome also increases vascular permeability due to rupture of endothelial inter-cell junctions so that, even without repositioning the twisted body, the release of inflammatory mediators is still possible. The neutrophil infiltration can be considered as another source of free radicals in ischemic tissue due to the stimulation of inflammatory mediators such as tumor necrosis factor and interleukin-1 (MOSTAJERAN et al., 2007). In this report, the correct clinical and surgical management were used to treat the patient; however, Fragata et al. (2008) reported that systemic lesions cannot be reversed, leading to dysfunction or multiple organ failure. An attempt to reduce tissue damage associated with free radicals could have been done using antioxidant drugs, which act specifically on certain metabolites such as deferoxamine mesylate (10 mg.kg⁻¹, IV-iron chelator), superoxide dismutase (5 mg/kg - catalyst degradation of superoxide radicals), dimethylsulfoxide (1g/kg), and hypertonic sugar or mannitol (0.5 to 2.0 g/kg⁻¹ IV), both of which capture free radicals (PAPICH, 2009).

The prognosis of uterine torsion varies from favorable to good, when quick response occurs, with support intensive care and OH (RIDYARD et al., 2000). In this case, the patient died four hours after surgery, probably due to delayed initial treatment, that is, the long time elapsed between the onset of clinical signs and demand for veterinary care, with consequent development of the shock syndrome still in the preoperative.

CONCLUSION

We conclude that uterine torsion in cats is an emergency condition with risk of death, and that treatment delay may make the cure impossible.

REFERENCES

CHAMBERS, B. A.; LAKSITO, M. A.; LONG, F.; YATES, G. D. Unilateral uterine torsion secondary to an inflammatory endometrial polyp in the bitch.

Australian Veterinary Journal, v.89, n.10, p.380-384, 2011.

DE LA PUERTA, B.; MCMAHON, L. A.; MOORES, A. Uterine torsion in a non-pregnant cat. *Journal of Feline Medicine and Surgery*, v.10, p.395-397, 2008.

FRAGATA, F. S.; MARQUES, A. F.; MANSUR, A. P. Choque: definições e tratamento em medicina veterinária. In: SANTOS, M. M.; FRAGATA, F. S. **Emergências e terapia intensiva veterinária em pequenos animais – bases para o atendimento hospitalar**. São Paulo: Roca, 2008, p.72-83.

GOMES, S. G. R. Transfusão sanguínea. In: SANTOS, M. M.; FRAGATA, F. S. **Emergências e terapia intensiva veterinária em pequenos animais – bases para o atendimento hospitalar**. São Paulo: Roca, 2008, p.172-190.

MERLO, A. Cristalóides e colóides. In: SANTOS, M. M.; FRAGATA, F. S. **Emergências e terapia intensiva veterinária em pequenos animais – bases para o atendimento hospitalar**. São Paulo: Roca, 2008, p.210-233.

MOSTAJERAN, F.; NADERI, M.; ADIBI, S. Effects of melatonin on histopathological changes after experimental ovarian torsion-detorsion in cat. *Iranian Journal of Reproductive Medicine*, v.5, n.4, p.177-181, 2007.

PAPICH, M. G. **Manual Saunders Terapêutico Veterinário**. 2.ed. São Paulo: MedVet, 2009, p.774.

RIDYARD, A. E.; WELSH, E. A.; GUNN-MOORE, D. A. Successful treatment of uterine torsion in a cat with severe metabolic and haemostatic complications. *Journal of Feline Medicine and Surgery*, v.2, p.115-119, 2000.

SILVA, S. B. Emergências do trato reprodutor feminino. In: SANTOS, M. M.; FRAGATA, F. S. **Emergências e terapia intensiva veterinária em pequenos animais – bases para o atendimento hospitalar**. São Paulo: Roca, 2008, p.330-342.

STANLEY, S. W.; PACCHIANA, P. D. Uterine torsion and metabolic abnormalities in a cat with a piometra. *Canadian Veterinary Journal*, v.49, p.398-400, 2008.

STONE, E. A. Ovário e útero. In: SLATTER, D. **Manual de cirurgia de pequenos animais**. 3ªed. Barueri: Manole, v.2, 2007, p.1487-1502.

THILAGAR, S.; YEW, Y. C.; DHALIWAL, G. K.;
TOH, I.; TONG, L. L. Uterine horn torsion in a
pregnant cat. **The Veterinary Record**, v.157, p.558-
560, 2011.